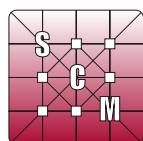


Sociedad de Ciencias Morfológicas de La Plata
(La Plata Morphological Sciences Society)

Resúmenes del XIV CONGRESO y 11^{avas} JORNADAS DE EDUCACIÓN
Abstracts from the XIV Congress and 11th Education Workshop



www.scmlp.org.ar



19 y 20 DE SEPTIEMBRE DE 2012
UNIVERSIDAD NACIONAL DE LA PLATA
FACULTAD DE ODONTOLOGÍA
LA PLATA, ARGENTINA

**ANATOMICAL FACTORS TO BE CONSIDERED IN THE APPROACH
TO THE EXTERNAL CAROTID ARTERY**

CARDOSO J; LANDIVAR RAMALLO A; SPALA M; SALAGOITY F; QUERAL M; ESBORRAT L.

Cátedra "C" de Anatomía, Facultad de Ciencias Médicas, UNLP. Calle 60 y 120 s/n, CP 1900. La Plata, Buenos Aires, Argentina.

e-mail: lucianoesborrat@yahoo.com.ar

In patients with advanced cancer who have already received chemotherapy, radiotherapy or surgery, the practitioner can meet the need of having to perform ligation of the external carotid artery, due to uncontrollable bleeding from one of its branches. It is important to note that, in these patients, anatomy is significantly altered because of the abovementioned treatments, and for this reason the professional should seek important anatomical elements to access the external carotid artery. Because the lingual artery collateral branch of the external carotid artery has a terminal type of irrigation, the external carotid ligation should be performed as far as possible above the emergence of the side branch, since performing it under it may result in necrosis of the lingual body. We used basic elements of dissection and seven human heads preserved in 10% formol to perform the external carotid ligation. We relied on an anatomical shelter: the Farabeuff triangle, and other anatomical elements of importance in the region, such as the internal jugular vein, venous trunk Tirolinguofacial, hypoglossal nerve, lingual artery and greater horn of the Hyoid bone. When the bleeding comes from branches of the external carotid artery, ligation can be tried to its source vessel. The relationship of the artery with the anatomic and surgical repairs is important for proper access and ligation.

Keywords: anatomical factors, carotid artery.

**MYOLOGICAL DESCRIPTION OF THE HINDLIMB OF
Myiopsitta monachus (AVES, PSITTACIFORMES)**

CARRIL J^{1,2}; MOSTO MC^{2,3}; PICASSO MBJ³.

1. Cátedra de Reproducción Animal, Facultad de Ciencias Veterinarias, UNLP. Calle 60 y 118 s/n, CP 1900. La Plata, Buenos Aires - Argentina. 2. CONICET. 3. División Paleontología Vertebrados, Museo de La Plata, UNLP. Paseo del bosque s/n, CP 1900. La Plata, Buenos Aires - Argentina.
e-mail: julytacarril@hotmail.com

The Psittaciformes is a homogeneous and well-defined clade that includes arboreal and climbing birds able to manipulate food, mainly due to their zygodactyl feet. However, their systematic diagram and affinities with other groups still remains under discussion. Myological descriptions are a data resource frequently used in phylogenetic and functional studies but poorly explored in the Psittaciformes. In this work, we studied, for the first time, the hindlimb myology of *Myiopsitta monachus* (Monk parakeet) and compared it with the description of *Amazona albifrons* (White-fronted Amazon) available. Six specimens of *M. monachus* were dissected under binocular magnifying glass. The main differences found were: the presence of one belly in the *m. iliofibularis*, the presence of the *m. ambiens* and the femoral origin of the *m. flexor perforatus digiti II*; the absence of the *m. extensor proprius digiti III accessorius* and the connection by a tendinous vinculum between the *m. flexor digitorum longus* and *m. flexor hallucis longus* tendons. The myological characterization of the hindlimb of *M. monachus* adds to the few known studies for other Psittaciformes and the differences found reaffirm the need to carry out further studies in more species of the group.

Keywords: monk parakeet, muscles, zygodactyl feet.

**MORPHOLOGICAL VARIATIONS IN THE ANTERIOR END OF THE LASTOMATID
NEMATODE PARASITES OF COCKROACHES**

CAMINO NB; GONZÁLEZ SE; RUSCONI JM.

Centro de Estudios Parasitológicos y de Vectores (CEPAVE) - CCT La Plata - CONICET - UNLP - CIC. Calle 2 n° 584, CP 1900. La Plata, Buenos Aires - Argentina.

e-mail: nemainst@cepave.edu.ar

The study of parasitic nematodes in cockroaches (Blattodea, Blattidae) in an abandoned house in La Plata (Buenos Aires, Argentina) revealed a generic variation in the anterior end of the body of telastomatid nematodes (Nematoda, Thelastomatidae), all simultaneous intestinal parasites of the insect, belonging to four different genera. The purpose of this study was to demonstrate the structure variability of the different species and its relation to parasitism. The parasites were killed in distilled water at 60 °C for 2 minutes and fixed in triethanolamine, formalin and distilled water (TAF). The results showed the presence of nematodes of the genera *Thelastoma*, *Hammerschmidtella*, *Blaticolla* and *Leidynema*. *Thelastoma* sp. presented a short stoma, esophagus with no median bulb, valvate basal bulb and small amphids. *Hammerschmidtella* sp. presented a cuticle with large rings, pore shaped amphids and an esophageal narrow triangular structure comprising a spherical strongly valvate median bulb and a valvate basal bulb. *Blaticolla* sp. presented oval amphids, a wide stoma and slightly ringed cuticle, esophagus with valvate median and basal bulb, but median bulb of cylindrical shape. *Leidynema* sp. presented sessile cephalic papillae, pocket-shaped amphids and toothed stoma, esophagus with cylindrical and slightly valvate median bulb, and strongly valvate basal bulb. In conclusion, we can say that this variation allows quick and easy identification of the different groups within the family Thelastomatidae.

Keywords: nematode parasites, cockroaches.

EVIDENCE OF DOUBLE MOLT OF THE CUTICLE BODY AND SIMPLE MOLTS IN THE ESOPHAGUS OF *Gastromermis* sp. (NEMATODA, MERMITHIDAE)

CAMINO NB¹; VERGARA V²; SALAS L².

1. Centro de Estudios Parasitológicos y de Vectores (CEPAVE) - CCT La Plata - CONICET - UNLP - CIC. Calle 2 n° 584, CP 1900. La Plata, Buenos Aires - Argentina. 2. Facultad de Ciencias Exactas y Naturales, Universidad Nacional de Catamarca, UNCa.
e-mail: nemainst@cepave.edu.ar

Gastromermis sp. (Nematoda, Mermithidae) is a nematode parasite of the midge *Simulium* (*Ectemnaspis*) *wolffhuegeli* (Diptera, Simuliidae) it was recollected in the The Tala River (Catamarca, Argentina), to observe whether living specimens revealed body molts along with the esophagus. The purpose of this study was to describe the process of shedding observed in this species. Nematodes were kept in Petri dishes with mineral water and coarse sand number 3, and observed daily under a stereomicroscope to remove dead individuals that could contaminate the environment with fungi. The molting was observed and digital pictures were obtained. As a result there was a molt in the body that swept down a juvenile form L3 together with the L4 juvenile form. This double change of the two cuticles was clearly stated on the back end. At the front end, in addition to the changes in the body wall, organs and cephalic papillae and amphids, we observed the simple molt of the esophageal wall. This work manifests the importance of the study of live specimens for the description of a species.

Keywords: silent, roundworm, *Gastromermis* sp.

**CRANIOFACIAL BONE REMODELING IN
PREHISTORIC HUMAN POPULATIONS OF ARGENTINA**

BRACHETTA-APORTA N; BERNAL V.

División Antropología, Facultad de Ciencias Naturales y Museo, UNLP. Paseo del Bosque s/n, CP 1900. La Plata, Buenos Aires - Argentina.
e-mail: nacha_bra@yahoo.com.ar

Craniofacial morphology observed in adult individuals results from modeling and remodeling mechanisms that underlie bone growth dynamics. Therefore, the study of these mechanisms is essential for understanding the histological basis of changes in shape and size. We present an approach that combines geometric morphometric techniques to quantify anatomical changes in shape with microscopic techniques that identify traits related to processes of bone formation and resorption. We analyzed a set of landmarks and semilandmarks on images of 52 skulls of human adults from Patagonia and Northwest Argentina to describe facial variation. The principal component analysis on these variables showed differences in the degree of development of the glabella and malar. Individuals representing the extremes of variation in shape were selected for high-resolution replicas of the glabella, superciliary arch and malar. The metalized surfaces of each cast were analyzed with a scanning electron microscope and an incident light optical microscope in order to identify: a) textures characterized by the presence of collagen fibers, which are evidence of formation processes, and b) lacunar textures produced by the action of osteoclasts in bone absorption regions. Finally, we compared the spatial distribution, shape and size of the areas of bone formation and absorption between individuals. The results are discussed in the context of the factors responsible for inter-population differentiation.

Keywords: histology, geometric morphometrics, population differentiation.

MASTOID PROCESS LENGTH AS AN INDICATOR OF SEXUAL DIMORPHISM

CARIAGA A¹; DESÁNTOLO B²; PAGGI R²; GARCÍA MN²; INDA AM².

1. Facultad de Ciencias Naturales y Museo; UNLP. 2. Cátedra de Citología, Histología y Embriología "A", Facultad de Ciencias Médicas, UNLP. Av. 60 y 120 s/n, CP 1900. La Plata, Buenos Aires - Argentina.

e-mail: barbaradesantolo@hotmail.com

The morphometric analysis is one of the main sources for sex estimation in human skeletal remains. The right assignation depends on the bone chosen and the reference standards. The mastoid process is one of the cranial traits used for such determination. This feature is larger in males, which would be related to the greater development of the muscles inserted there. The present study aimed to establish whether there are significant differences in the total length of the mastoid process between sexes. The sample analyzed belongs to the Prof. Dr. Rómulo Lambre Osteological Collection (FCM-UNLP), which is composed of skeletal remains of well-documented individuals. The morphometric analysis was performed with a digital caliper (accuracy 0.01mm), and the data achieved were statistically analyzed using SPSS-17.0 software. The results allowed us to determine the discriminate power of this anatomic feature, always considering that the expression of sexual dimorphism is closely related to the biology of the group and strongly influenced by both physical and cultural environmental factors.

Keywords: mastoid, sex, morphometry.

SEX DETERMINATION FROM MANDIBULAR CANINE INDEX

GARIZOAIN G; PLISCHUK M; GARCÍA AL; ERRECALDE AL; INDA AM.

Cátedra de Citología, Histología y Embriología "A", Facultad de Ciencias Médicas, UNLP. Calle 60 y 120 s/n, CP 1900. La Plata, Buenos Aires - Argentina.

e-mail: marcosplischuk@yahoo.com.ar

In Forensic Sciences, the analysis of dental pieces becomes of great importance since it gives valuable information because teeth are better preserved than the rest of human bones. One of the assumptions often used is that male teeth show a greater size than female ones. In the present study, we analyzed the accuracy of the Mandibular Canine Index (MCI) as a sex indicator in a well-documented, contemporary and regional skeletal sample. In order to accomplish our objective, we selected a representative sample from the Osteological Collection "Prof. Dr. Romulo Lambre" hosted in the Laboratory of "Citología, Histología y Embriología A" from the Facultad de Ciencias Médicas (Universidad Nacional de La Plata, Buenos Aires, Argentina). The individuals selected for the analysis had a complete mandible and preserved at least one of their canines. Subsequently, we carried out morphometric analysis that consists in measuring the mesiodistal diameter of the canine crown and the maximum width of the mandibular arch (distance between canines or between the present canine and the alveolar bone corresponding to the missing canine). Such measurements were performed with the help of a digital caliber (0.01mm accuracy). Finally, the MCI was estimated as the quotient between the mesiodistal diameter of the canine crown and the maximum width of the mandibular arch, considering a critical value of 0.274. Results were compared with the documentary collection data with the aim to analyze the accuracy of this method.

Keywords: sex, canine, mandibular, index.

CHARACTERIZATION OF THE NUTRITIONAL STATUS, ENTEROPARASITOSSES AND SOCIO-ENVIRONMENTAL CONDITIONS IN THE INFANT-JUVENILE POPULATION OF LA PLATA DISTRICT (ARGENTINA)

OYHENART EE^{1,2}; GARRAZA M²; BERGEL ML¹; TORRES MF^{1,3}; CASTRO LE¹; CESANI MF²; FORTE LM⁴; GAMBOA MI⁵; LUIS MA¹; LUNA ME²; QUINTERO FA^{1,2}; ZONTA ML⁵; NAVONE GT⁵.

1. Cátedra de Antropología Biológica IV, Facultad de Ciencias Naturales y Museo, UNLP. Calle 64 N°3, CP 1900. La Plata, Buenos Aires - Argentina. 2. Instituto de Genética Veterinaria (IGEVET), Facultad de Ciencias Veterinarias, UNLP - CCT La Plata - CONICET. 3. Facultad de Filosofía y Letras, Universidad de Buenos Aires. 4. Instituto de Geomorfología y Suelos, Facultad de Ciencias Naturales y Museo, UNLP. 5. Centro de Estudios Parasitológicos y de Vectores (CEPAVE) - CCT La Plata - CONICET - UNLP.

e-mail: oyhenart@fcnym.unlp.edu.ar

The aim of this work was to determine the nutritional status, enteroparasitoses and socio-environmental conditions of children dwelling in 13 localities of La Plata district, Province of Buenos Aires (Argentina), by means of a transversal study. Body weight, total and sitting height, arm circumference and tricipital skinfold were measured in 6,397 children aged between 4.0 and 13.9 years old. The body mass index, the Cormic index and muscular area of the arm were calculated and the nutritional status and body composition and proportions were estimated using NHANES III. Socio-environmental variables were obtained through structure questionnaires. Parasitological analysis was made in 729 children using serial samples of fecal material collected by the parents and processed with the Ritchie technique and serial anal brushes. General results indicated 22.1% of excess of weight, 8.7% of undernutrition and 68.5% of parasitoses. *Enterobius vermicularis* (38.6%) and *Blastocystis* sp. (36.0%) were the most prevalent parasites, while geohelminths and nonpathogenic protozoa were less prevalent. La Plata district presents a great internal heterogeneity in the variables analyzed. The lack of environmental sanitation, the low level of education, and the lack of formal jobs may explain the occurrence of parasitoses and undernutrition in children from Villa Elvira, Los Hornos and Melchor Romero localities whose changes in body composition and proportions were observed. On the other hand, children of City Bell, Tolosa and Villa Elisa, whose parents presented higher education levels and more stabilized jobs -although with deficient sanitary conditions of residence-, presented a higher prevalence of excess of weight.

Keywords: malnutrition, socio-environmental conditions, enteroparasitoses.

MODIFICATION OF THE CRANIOFACIAL GROWTH RESULTING FROM POSTNATAL NUTRITIONAL REHABILITATION IN RATS WITH INTRAUTERINE GROWTH RETARDATION

LUNA ME¹; QUINTERO FA^{1,2}; CESANI MF¹; FUCINI MC^{1,3}; GUIMAREY LM^{1,4}; VILLANUEVA M⁵; PRIO V⁵; OYHENART EE^{1,2}.

1. IGEVET, Facultad de Ciencias Veterinarias, UNLP - CCT La Plata - CONICET. 2. Cátedra de Antropología Biológica IV. Facultad de Ciencias Naturales y Museo, UNLP. 3. Cátedra de Radiología, Facultad de Odontología, UNLP. 4. Fundación de Endocrinología, Nutrición Infantil y Crecimiento. 5. Servicio de Diagnóstico por Imagen, Facultad de Ciencias Veterinarias, UNLP. Instituto de Genética Veterinaria - CCT La Plata - CONICET - Facultad de Ciencias Veterinarias, UNLP. Calle 60 y 118 s/n, CP 1900. La Plata, Buenos Aires - Argentina.

e-mail: lunamariaeugenia@hotmail.com

The aim of this work was to analyze the effect of lactational and post-lactational nutritional rehabilitation of cranial growth in rats with intrauterine growth retardation. Wistar rats were divided into two groups: Control (C) and Intrauterine Growth Retardation (IUGR). The IUGR group was constituted by offspring whose mothers received partial ligation of both uterine arteries on day 15 of gestation. The mothers during gestation and lactation as well as the offspring during post-weaning were fed on stock diet *ad libitum*. The animals were x-rayed on days 1, 21 and 84 of postnatal life. Neurocranial and splanchnocranial length, width and height were measured on each radiograph. Neural (NVI) and facial (FVI) volumetric indices were calculated. Kolmogorov-Smirnov test, multivariate analysis of variance, least squared post-hoc test and discriminant analysis (DA) were performed. The results indicated significant differences in age, sex and treatment between the C and IUGR groups. The comparison between C and IUGR NVI and FVI showed significant differences in both sexes at birth and in males on day 21. On day 84, males had significant differences only in NVI and females in NVI and FVI. The DA differentiated treatment and sex in all ages. The results obtained show the effect caused by prenatal stress, even when mediating nutritional rehabilitation. Cranial recovery depends on the sex and region analyzed. In males, facial compensatory growth occurs belatedly, whereas in females, although they recover the cranial size during lactation, they present growth retardation again.

Keywords: experimental anthropology, intrauterine growth retardation, postnatal nutritional rehabilitation.

**FACTORS AFFECTING UNIVERSITY STAY AT THE SCHOOL OF NATURAL SCIENCES AND
MUSEUM OF THE UNIVERSITY OF LA PLATA (ARGENTINA)**

CAMINO NB; GONZÁLEZ SE.

Facultad de Ciencias Naturales y Museo, UNLP. Calle 60 y 122 s/n, CP 1900. La Plata, Buenos Aires - Argentina.

e-mail: nemainst@cepave.edu.ar

From its beginnings, the public University of La Plata (Buenos Aires, Argentina) has tried to analyze and elucidate the failure and dropout in the first years of university life. It has been found that this is due to psychological, sociological, economic, and organizational factors or to the students' interaction with the institution. Since 1968, a value has been assigned to the social composition of new students as another factor involved. In the present study, four cohorts of students of the General Zoology course of the first year of the Masters in Biology were statistically analyzed, with the following results: 47.22% (2008), 51.76% (2009), 50.66% (2010), and 51.61% (2011) of students dropped out. We found that several variables were involved in this dropout: a) the student's prior education and counseling; b) demographic variables; c) the student's employment status; and d) the cultural level of the student's parents. These variables influenced the dropout either independently or in an interrelated manner. Since 2009, a tutorial system has been implemented in the School of Natural Sciences and Museum of the University in La Plata. It is expected that over time, this system is accepted and profited massively by the students, increasing the retention of students due to the neutralization of any of the above variables.

Keywords: dropout, new students, biology.

ANALYSIS OF THE ACADEMIC PERFORMANCE OF STUDENTS IN A BIOCHEMISTRY COURSE AT THE SCHOOL OF VETERINARY SCIENCES - UNIVERSITY OF LA PLATA (BUENOS AIRES, ARGENTINA)

REBOREDO GR; GAVAZZA MB; TERRASA AM; MARMUNTI ME; PIERGIACOMI VA; GUTIÉRREZ AM; LEADEN PJ; ZEINSTEGER PA; PALACIOS A.

Cátedra de Bioquímica, Facultad de Ciencias Veterinarias, Universidad Nacional de La Plata. Calle 60 y 118 s/n, CP1900. La Plata, Buenos Aires - Argentina.

e-mail: greboredo@yahoo.com.ar

Biochemistry is a first-year course at the School of Veterinary Science of the University of La Plata (Buenos Aires, Argentina). For any educational institution, it is important to understand the factors that impact on students' academic performance. Here, we analyzed the academic results of students from the 2011 Biochemistry course. From 859 students (494 freshmen and 365 repeating the course) 226 passed, being 46.7% freshmen and 53.3% repeating the course. We also observed that 23.08% of the freshman students abandoned the course before the first partial examination (due to unfinished courses at the secondary school, etc.). The analysis of the results of partial exams of the three parts in which the course is organized allowed us to detect that 324 students failed the course in the first part, with 57.7% students that disapproved and 42.3% that did not take the exam; that 184 students failed in the second part (86.4% disapproved, 13.6% did not take the exam); and that only 8 students abandoned the course in the last part. We concluded that the low performance of the students might be due to the following reasons: unfinished courses at the secondary school, high dropout rate, lack of interest and study habits.

Keywords: academic performance, dropout, biochemistry.

TEACHERS' PERFORMANCE EVALUATION BASED ON STUDENTS' OPINION

TOSTI SB; PEÑALVA MA; CECHO AC; SANBARTOLOMEO PM.

Facultad de Odontología, Universidad Nacional de La Plata. Calle 50 e/ 1 y 115, CP 1900. La Plata, Buenos Aires - Argentina.

e-mail: sobetis@yahoo.com.ar

University education poses several questions. The most frequent are: Is teaching good?, What does "effective teaching" mean?, Is there any relationship between good teaching and students' learning? We cannot separate teaching from the teaching task. A valuable tool for teacher's evaluation is through feedback from students, as it provides tools to guide learning processes, design plans and curricula and form a solid faculty. It allows improving teaching and relationships with students, and creating a suitable learning space to incorporate new knowledge, behaviors and skills. The objective proposed was to provide teachers with a self-assessment and self-criticism to implement strategies that will improve their performance in the classroom. The teachers chosen were those of the subject Physiology of the School of Dentistry of the University of La Plata (Buenos Aires, Argentina) teaching students during the second semester of 2011 (450 students). We evaluated: 1) methodological strategies, 2) knowledge of the subject, 3) interaction with students, and 4) commitment to teaching. Surveys were used to answer 20 Yes or No questions in 10 minutes, with the following results: 1) 65% Yes; 2) 82% Yes; 3) 33% Yes; 4) 56% Yes. These data show that teachers should improve the four pillars evaluated.

Keywords: teacher's performance, student's opinion, evaluation.

ALTERNATIVE CONCEPTS IN PHYSIOLOGY

PEÑALVA MA; TOSTISB; CECHO AC.

Facultad de Odontología, Universidad Nacional de La Plata. Calle 50 e/ 1 y 115, CP1900. La Plata, Buenos Aires - Argentina.

e-mail: anahipenalva@hotmail.com

In the present study, we performed an initial diagnostic evaluation on 78 students of Physiology I of the Faculty of Dentistry of the University of La Plata (Buenos Aires, Argentina), considering the systematization of the intuitive principles and heuristics processes of Talanquer (2005), with the purpose to identify intuitive principles and heuristic reasoning processes of alternative concepts in students. Before the class, students were given an open questionnaire regarding circulation. The following intuitive principles and heuristic processes were categorized in the evaluation: *essentialism*: refers to nature as an independent existence without relating to the context; *association*: a) *proximity*: tendency to associate elements close in space, b) *availability*: tendency to identify different phenomena based on their cognitive availability; and *reduction*: simplifies the interpretation of phenomena. Of 390 questions, 102 were not answered and 18 were answered correctly. With regard to alternative concepts, the intuitive principle of essentialism was repeated 18 times, reduction was repeated 180 times, and proximity 34 times. Results showed that many questions were not completed and that students significantly reduced or simplified the concepts about circulation. A small number of students had taken the exam of Anatomy and Histology recently. This allowed them to show the learned concepts. In the description of irrigation, several students referred to close anatomical elements. The essentialist conceptualizations involve relevant errors.

Keywords: alternative, conceptions, movement.

**APPROACH TO THE CONCEPTIONS OF EVALUATION HELD BY FIRST YEAR STUDENTS
FROM A SCHOOL OF VETERINARY SCIENCES**

VILLACORTA A¹; PINGITORE C¹; ELISSONDO M²; GENTILE M²; FELIPE A².

1. Área de Aprendizajes en Ciencia y Tecnología; 2. Departamento de Ciencias Biológicas, Facultad de Ciencias Veterinarias, Universidad Nacional del Centro de la Provincia de Buenos Aires. Campus Universitario, CP 7000. Tandil, Buenos Aires - Argentina.

e-mail: claudiapingitore@hotmail.com

Evaluation at university level should become an improving learning process instead of a control strategy about what the student knows, and an act of qualifying. The aim of this study was to identify the conceptions of evaluation of first-year students from the Facultad de Ciencias Veterinarias - Universidad Nacional del Centro de la Provincia de Buenos Aires (Tandil, Argentina). We worked with an exploratory research scheme developing a closed questionnaire with 10 polychotomous options of verbal analogic coding in a Likert-type scale. Its reliability was determined by interobserver agreement and content validation. The survey was conducted by simple random sampling to 45 students in a classroom situation. Students considered that the evaluation should be a continuous process, an integral part of teaching and learning (96%), although, from their actual experiences, it was perceived as a final stage of these processes (78%). Most of them thought that the evaluation was a part of what happens during a course (95%) and only one way to measure what they know (69%). They considered that it is neither neutral nor bereft of values (60%), that it has a positive impact on the learning environment (73%), and that it should not be a way of exercising control (60%). The students' conceptions constitute a cognitive substrate to be taken into account for implementing proposals to improve the most frequent evaluation practices at universities, since, in most cases, they are consistent with them.

Keywords: evaluation, conceptions, students.

DIFFERENT STRATEGIES IMPLEMENTED IN THE TEACHING OF HISTOLOGY AND EMBRYOLOGY

PAGGI RN; IVANOV M; MAYOCCHI KA.

Asignatura Histología y Embriología, Facultad de Odontología, Universidad Nacional de La Plata. Calle 50 e/ 1 y 115, CP 1900. La Plata, Buenos Aires - Argentina.

e-mail: karinamayocchi@hotmail.com

This work comes from different classroom strategies implemented during the first semester of 2012 of the Course of Histology and Embryology II of the Faculty of Dentistry of the University of La Plata (Buenos Aires, Argentina). The aim of this study was to evaluate different learning strategies. To accomplish this, we evaluated three different methodologies: *Traditional Methodology*, where the teacher develops the theme allowing the participation of students, with poor response of them; *Guided Study Groups*, with groups of 4 to 5 students who were given a questionnaire guide as well as literature and media support, and the teacher played an oversight role; and *Directed Study with Inclusion of Technology*, with groups of 4 to 5 students who were given a questionnaire identical to that used in the Guided Study Groups, choosing words that facilitated Internet search technology. In the *Traditional Methodology*, 22 students were evaluated, with an average score of 5.85 in the 1st exam and of 5.44 in the 2nd exam; six of them had scores over 7, with an average score of 7.16; in the *Guided Study Groups* 25 were evaluated, with average scores of 4.64 in the 1st exam and of 5.80 in the 2nd exam; seven of them had scores over 7, with an average score of 7; in the *Directed Study with Inclusion of Technology*, 23 students were evaluated, with average scores of 7.00 and 5.70 in the 1st and 2nd exams respectively; eight of them had scores over 7, with an average score of 7.37. We concluded that the Guided Study Groups gets closer to university curriculum requirements based on the guiding teacher and involves students in a self-learning process. By incorporating technology, effective learning is achieved, including the student to the knowledge society.

Keywords: strategies, methodologies, questionnaire-guide.

GUIDE OF ACTIVITIES OF ANIMAL ANATOMY AND PHYSIOLOGY AS AN INTERDISCIPLINARY TOOL FOR AGRICULTURAL ENGINEERING

GALÁN AM¹; MOINE R¹; MAYER N²; NATALI J¹; FIORETTI C¹; GIGENA S¹; MOUGUELAR H¹; VARELA M¹; RIVERA MC¹; POLONIL²; RODRÍGUEZ N².

1. Anatomía, Facultad de Agronomía y Veterinaria. 2. Fisiología, Facultad de Ciencias Exactas, Físico-Químicas y Naturales. Universidad Nacional de Río Cuarto. Ruta Nac. 36, km 601, CP 5800. Río Cuarto, Córdoba - Argentina.

e-mail: mgalan@ayv.unrc.edu.ar

The development of a guide of activities from an interdisciplinary approach results from a long process that attempts to integrate the knowledge of the areas of Animal Anatomy and Physiology for students of Agricultural Engineering. Since this course is currently dictated in a fragmented way, the faculty proposed the articulation of anatomical and physiological knowledge, as a better alternative. In order to do this, contents were selected and restructured according to the professional profile, which generated changes in the structure of the subject and its methodology. We then proposed to develop a guide of interdisciplinary activities to orient students in an integrated learning. The activity guide includes: information concerning its use and purpose, title and objectives of the subject, and learning activities. For the development of the activities, relevant aspects of the content of the two disciplines were selected and represented in charts, drawings, questions and problem situations. Innovations were evaluated in the 2012 course, through a survey of students. The results were: 87% of students considered that the activities of the guide are good and facilitated the study, 95% said it is important to integrate knowledge and 88% integrated knowledge of Anatomy and Physiology. The activity guide promotes the articulation of integrated knowledge through appropriation and application activities and ensures meaningful learning.

Keywords: guide, integration, interdisciplinarity.

EDUCATIONAL EXPERIENCE USING VIDEOS IN THE ANALYSIS OF HISTOLOGICAL PREPARATIONS IN THE COURSE OF HISTOLOGY OF THE SCHOOL OF DENTISTRY OF THE UNIVERSIDAD DE LA REPÚBLICA (MONTEVIDEO, URUGUAY)

TAPIA G.

Facultad de Odontología, UdelaR. Carlos Crocker 2586, CP 12000. Montevideo, Uruguay.

e-mail: gtapia2204@gmail.com

The aim of this study was to incorporate the video as a new tool to learn Histology in the Virtual Learning Environment of the Department of Histology of the School of Dentistry of the Universidad de la República (Uruguay). The aim was to know the value of students regarding the Virtual Learning Environment. We performed a cross-sectional study and observations, seeking to evaluate the implementation of EVA using Moodle Platform Unit 1 students of the course of Biological Basis of Dentistry, Faculty of Dentistry, Universidad de la República, Montevideo - Uruguay. The platform was used to support the classroom course in 2012. We analyzed the experience with five groups of students. We analyzed different elements on the virtual environment, involving the performance of teachers and students Participation in Forums, and proposed possible changes to improve the tool. We implemented a teaching and learning strategy that has a high percentage of approval of the participants.

Keywords: educational experience, videos, histology.

EDUCATIONAL EXPERIENCE WITH THE USE OF EVA ABOUT THE USE OF VIDEOS IN THE ANALYSIS OF HISTOLOGICAL PREPARATIONS IN THE COURSE OF HISTOLOGY OF FACULTAD DE ODONTOLOGÍA - UNIVERSIDAD NACIONAL DE LA REPÚBLICA, MONTEVIDEO, URUGUAY

TAPIA G.

Facultad de Odontología, UdelaR. Carlos Crocker 2586, CP 12000. Montevideo, Uruguay.

e-mail: gtapia2204@gmail.com

The video is a new tool in Histology Virtual Learning Environment of the Department of Histology of the School of Dentistry of the University of la República, Montevideo, Uruguay. We performed a cross-sectional study and observations, seeking to evaluate the implementation of videos as a complementary tool to study the histological preparations that are addressed in Unit 1 of BBO Courses in the School of Dentistry of the University of la República, Montevideo, by the use of the Moodle platform. The material was used to support the art classroom course in 2012. The sample consisted of 25 students. Different elements such as Virtual Environment, teacher performance and perception of members on the instruments were analyzed. We implemented a teaching and learning strategy that has a high percentage of approval of the participants. We concluded that videos impact positively on perception.

Keywords: educational experience, EVA, histology.

CONTROL OF DENTAL CARIES THROUGH SPECIFIC PROTECTION

ARCURI A; CIRIMARCO C; ARCURI M; MATTANÓ C; BERNARDI H.

Patología y Clínica Estomatológica, Facultad de Odontología, UNLP. Calle 50 e/1 y 115, CP 1900. La Plata, Buenos Aires - Argentina.
e-mail: claudiamattano@yahoo.com.ar

Caries is a multifactorial disease that has increased due to socio-economic problems that leads people to suffer from different nutritional and developmental disorders, and in many cases lack of access to preventive treatments for health. Caries stems from the bacterial plaque, and a diet rich in carbohydrates and poor or no oral hygiene factors is involved in its development objectives: To relate the presence of plaque with a cariogenic risk index, to teach appropriate prevention measures; to raise community awareness about the importance and need for the application of a proper brushing technique. Material and Methods: The study population consisted of 75 students of both genders, aged 19-23 years, of third year of the School of Odontology of the University of La Plata (Buenos Aires, Argentina). We recorded their medical history, dental chart and the selected plaque index, the O'Leary Index. We then motivated the students on how to use a proper brushing technique, the Bass Technique, and applied topical fluorides. Students were checked 3 and 7 months later using again O'Leary Index. Results: About 48% of the students selected reduced the cariogenic risk, 29% showed no significant variation, 17% did not change their behavior and thus kept the same index, and the remaining 6% increased the value of the index. Conclusion: Caries is a multifactorial disease that originates in plaque. A diet rich in carbohydrates and poor or no oral hygiene are factors in its development. There are various measures of prevention to control the cariogenic risk, but, considering the community needs, we believe that specific protection is a viable method.

Keywords: caries, specific protection, fluorine.

PERMANENCE OF FIRST PERMANENT MOLAR IN YOUNG ADULTS

CIRIMARCO C; MATTANÓ C; ARCURI A; ARCURI M; BERNARDI H.

Patología y Clínica Estomatológica, Facultad de Odontología, Universidad Nacional de La Plata. Calle 50 e/ 1 y 115, CP 1900. La Plata, Buenos Aires - Argentina.

e-mail: claudiamattano@yahoo.com.ar

First molars are the ones that initiate the eruption of permanent teeth in the oral cavity. First molars begin to calcify during the first month of life in the early stages of development and are one of the most important dental structures for the development of an adequate physiologic occlusion and masticatory function. Their complex anatomy favor the development and accumulation of microorganisms on their surface and consequently of various pathologies. Losing the first molars at an early age can cause alterations in the development and function of the stomatognathic system, including a decrease of 50% in the efficiency of mastication, as there is an imbalance of the masticatory function. The aims of this study were to assess the health status of adult patients, to evaluate which pathologies are the grounds for the early loss of the first molars, to motivate the community to preserve their health, to encourage the patient to remain in adult health. To this end, we conducted a survey of 30 patients who attended the clinic of Pathology of the Faculty of Dentistry of the University of La Plata (Buenos Aires, Argentina) in 2011 and compiled a medical history, dental examination and appropriate dental chart. The data were processed using statistical methods, taking into account the health or illness of the first permanent molar. In over 120 pieces analyzed, we found 20 healthy parts (16.6%), 40 with obvious presence of caries (33.3%), 23 sealed (19.16%) and 37 parts absent (30, 83%). We concluded that it is extremely important to maintain proper oral health by highlighting a proper brushing technique, proper eating habits and regular dental check-ups to keep the gnathic system health in good condition.

Keywords: first molar, caries, health.

WERE YOU ASKED IF YOU WANTED TO SMOKE?

MATTANÓ C; OVIEDO ARÉVALO J; BERNARDI H; ARCURI M.

Patología y Clínica Estomatológica, Facultad de Odontología, Universidad Nacional de La Plata. Calle 50 e/ 1 y 115, CP 1900. La Plata, Buenos Aires - Argentina.

e-mail: claudiamattano@yahoo.com.ar

In Argentina, 68.2% of adolescents are exposed to cigarette smoke. Many of the health risks depend on the smoking load and the daily consumption of cigarettes. The respiratory system has its own way of cleaning and has cilia responsible for removing dust. For every cigarette consumed, we also inhale a toxic mix of gases and air that has more than 4,000 different kinds of chemicals, irritants and carcinogens. After smoking, the person keeps the smoke in his/her lungs for more than eight hours, and the smoke takes long to leave the respiratory system. This causes various respiratory diseases, including pulmonary emphysema and cancer, not only in the airways but also in the oral cavity. Passive smoking causes 600,000 deaths a year, of which 31% are under age. Our aim is to reduce the consumption of cigarettes in adolescents aged 9-12 years as Oral Cancer Prevention and to sensitize educators and family to act as multipliers in prevention. To this end, we studied adolescents aged 10 to 12 years and carried out non-binding surveys, informative talks to parents and teachers, and educational workshops for teenagers. We concluded that 55% of teenagers start smoking at an early age; 38% of them do it to copy their parents, 35% to imitate their friends and the remaining 27% because it makes them feel older. Teenagers start smoking at a young age because they feel cigarettes position them in a certain social status and to imitate their idols, but they ignore the serious health complications caused by smoking both to them and to those surrounding them.

Keywords: adolescent, smoking, cancer, emphysema.

SUPPORTING THE PATIENT FACING SURGERIES IN THE SUBJECT SURGERY

RICCIARDI AV; BOGO H; RICCIARDI N; CAPRARO MC; SPARACINO S; MATTANO C; GOLDBERG D; CAPRARO C; CAPRARO ME.

Cirugía "A", Facultad de Odontología, Universidad Nacional de La Plata. 50 e/ 1 y 115, CP1900. La Plata, Buenos Aires - Argentina.
e-mail: sparasandra@hotmail.com

Anxiety and psychosomatic disorders are related. The persons' behavior affects their dental health either positively or negatively. In the same way, certain diseases or dental problems affect the behavior of those suffering from them. In a dental situation, although fear and anxiety are almost undistinguishable, the term dental anxiety prevails. Endler describes the following situational areas: interpersonal anxiety, anxiety before situations of physical danger, anxiety caused by facing new situations, anxiety when confronted with social judgment, and anxiety caused by dealing with everyday life. The aim of this research was to study the incidence of the social environment on the patient's anxiety during the surgery. To this end, we used the GAD Test, and the anxiety diagnosis criteria were: positive answer to A, B and C (see below); and positive answer to at least three items of C. A) You are anxious and excessively worried prior to visiting the dentist. B) It is hard for you to keep the situation under control. C) Anxiety and worry are associated with three or more of the following symptoms: nervousness, impatience, tiredness, trouble to get concentrated, irritability, muscular tension, sleep disorders. D) Anxiety causes alterations in the relationship with your family, friends or work colleagues. This is an orientative and self-manageable test. After 24 days, the results were as follows: 70% were females, the average age was 45 years, 78% showed anxiety at the onset of the treatment, and 44% of them showed anxiety once the treatment had finished. The identification of anxiety enables students and teachers of Surgery to support the patient properly during the surgery.

Keywords: anxiety, surgery, psychosomatic.

HOW DO STUDENTS SHOW STRESS AND FEAR WHEN FACING THE FIRST SURGICAL EXPERIENCE?

RICCIARDI AV; CAPRARO C; CAPRARO MC; SPARACINO S; CAPRARO ME; GOLDBERG D.

Facultad de Odontología, Universidad Nacional de La Plata. Calle 50 e/ 1 y 115, CP 1900. La Plata, Buenos Aires - Argentina.

e-mail: sparasandra@hotmail.com

Psychological stress is the result of a particular relationship between the individual and the environment. This relationship is considered by the individual as threatening or overwhelming and as dangerous for his/her welfare. In 1981, Maslach and Jackson discovered a syndrome appearing frequently in health professionals, known as the burnout syndrome. The student of Dentistry undergoes degrees of stress and anxiety that may influence directly in his or her performance. The purpose of this work was to study the incidence of the social context on the patient's anxiety during surgery. The sample consisted of students and patients attending the subject Surgery "A" at the School of Dentistry of La Plata, University of La Plata, Buenos Aires, Argentina. Questionnaires were done and adapted. Students and patients were responsible for making the questionnaires. Results obtained were as follows: 70% evidenced some degree of stress, being the main cause the fear to the unknown. Among them, 54.8% were women and 45.2 % were men. Results showed that women suffered more causes of stress than men. The patients and students surveyed showed high emotional fatigue and depersonalization and low self-fulfillment. Identifying the biological, physical, psychological and environmental risks implied in the Dental practice would help to minimize their effects.

Keywords: stress, surgery, burned.

EMBRYONIC DEVELOPMENT AND ITS FORMS, IN THE NEMATODE *Heterorhabditis bacteriophora* (RHABDITIDA: HETERORHABDITIDAE), A PATHOGEN OF INSECT PESTS

ACHINELLY MF; CAMINO NB; ELICECHE D; SALAS A.

Centro de Estudios Parasitológicos y de Vectores (CEPAVE) - CCT La Plata - CONICET - UNLP - CIC. Calle 2 n° 584, CP 1900. La Plata, Buenos Aires - Argentina.

e-mail: nemainst@cepave.edu.ar

Species of the genus *Heterorhabditis* are entomopathogenic nematodes mutually associated with enteric bacteria, which are used worldwide for the biological control of insects. These species control a long and important list of hosts. In this study, we studied the different forms of the embryonic development of *Heterorhabditis bacteriophora*, a species found in Buenos Aires (Argentina). To this end, hermaphrodite females, obtained by dissection of infected insects (*Galleria mellonella* and *Tenebrio* sp.) between the fourth and sixth day, were used in the first generation. Because development occurs within the body of the female, developmental stages were identified by low-transparency slides and coverslips. We found one egg, two blastomere states, three blastomeres (characteristic of nematodes), several blastomeres, and one monodermal form of embryo with a cavity (blastocoel) corresponding to the blastula. We noted gastrulation and vermiform embryo I and II. Finally, we found juveniles J1, J2 and J3. The latter emerges from the egg and retains the J2 cuticle, then larvae become "dauer" or refractory, which is the infectious form. This is the first detailed study of the forms of embryonic development of species of the genus *Heterorhabditis*, and thus represents a novel study.

Keywords: united, embryonic development, nematode.

HISTOCHEMICAL STUDY OF THE HEPATOPANCREAS OF
Cyrtograpsus angulatus (GRAPSOIDEA, VARUNIDAE)
AT LOW SALINITY CONDITIONS

COHEN S; LONGO MV; DÍAZ AO.

Instituto de Investigaciones Marinas y Costeras (IIMyC), Dpto. Biología, FCEyN. CONICET. Universidad Nacional de Mar del Plata. Funes 3250, 3° Piso, CP7600. Mar del Plata. Buenos Aires - Argentina.

e-mail: mvlongo@mdp.edu.ar

The aim of this study was to analyze the histochemical distribution of glycoproteins (GPs) and lipids in the hepatopancreas of *Cyrtograpsus angulatus* at low salinity conditions. To this end, adult male crabs in intermoult, collected from Mar Chiquita lagoon (Buenos Aires, Argentina), were acclimated in aquaria at 10 ‰ of salinity. Sections of the hepatopancreas were treated with the following techniques: AB (pH 2.5, 1.0, 0.5), AT (pH 4.2, 5.6), PAS, -amylase/PAS, Sudan Black and Red. The cytoplasm of E and F cells had moderate contents of GPs with oxidizable vicinal diols. The brush border, the peritrophic membrane and the vacuoles of B cells showed GPs with carboxyl, sulphated and very sulphated groups, and exhibited metachromasia with AT at pH 5.6. Moderate glycogen content was found in the vacuoles of B cells and the cytoplasm of R cells. Abundant lipid droplets were observed in the vacuoles of R cells and the cytoplasm of all cell types, except E cells. The composition and distribution of GPs and lipids in the hepatopancreas of *C. angulatus* acclimated at low salinity conditions would be related to the role of each cell type in the digestive process.

Keywords: *Cyrtograpsus angulatus*, hepatopancreas, histochemistry.

HISTOCHEMICAL STUDY OF THE ESOPHAGUS OF THE ARGENTINE ANCHOVY,
Engraulis anchoita, IN ADVANCED STAGES OF DEVELOPMENT

COHEN S¹; DÍAZ MV²; DÍAZ AO¹.

1. Laboratorio de Histología e Histoquímica, Instituto de Investigaciones Marinas y Costeras (IIMyC), Dpto. Biología, FCEyN. CONICET. Universidad Nacional de Mar del Plata. Funes 3250, 3° Piso, CP 7600. Mar del Plata. Buenos Aires - Argentina. 2. Instituto Nacional de Investigación y Desarrollo Pesquero (INIDEP).

e-mail: stefaniacohen@hotmail.com

The Argentine anchovy, *Engraulis anchoita*, is a species with great fishing potential, which, due to the fishing current situation, is on the way to be exploited intensely. The aim of this study was to analyze the histochemical distribution of glycoproteins (GPs) in the esophagus of larvae of *E. anchoita* in advanced stages of development. Histological sections of larvae of this species from the population of Buenos Aires (Argentina) were treated with histochemical techniques to differentiate GPs: with carboxyl groups and/or with ortho-sulphated esters (AB pH 2.5, 1.0 and 0.5; AT pH 4.2 and 5.6), with oxidizable vicinal diols and/or glycogen (PAS -amylase/PAS), with sialic acid residues (KOH/PA*S), with sialic acid residues with substitutions O-acyl at C7, 8, 9 and O-acyl sugars (PA/Bh/KOH/PAS) and neutral sugars (KOH/PA*/Bh/PAS). Mucous cells reacted strongly with all the histochemical techniques and metachromasia was observed with AT at both pHs, revealing GPs with high concentrations of oxidizable vicinal diols, GPs with sialic acid residues with substitutions at C7, 8 and/or 9 and highly sulphated GPs. The secreted GPs would be involved in lubrication, protection against abrasion and proteolytic degradation, antimicrobial function, and osmotic and ionic regulation.

Keywords: histochemistry, glycoproteins, *Engraulis anchoita*.

HISTOCHEMICAL CHARACTERIZATION OF THE MUSCULATURE OF THE PECTORAL FINS OF *Cynoscion guatucupa*

DEVINCENTI CV; LONGO MV; GONZÁLEZ CASTRO M; DÍAZ AO.

Instituto de Investigaciones Marinas y Costeras (IIMyC), Dpto. Biología, FCEyN. CONICET. Universidad Nacional de Mar del Plata. Funes 3250, 3° Piso, CP7600. Mar del Plata. Buenos Aires - Argentina.

e-mail: cdevin@mdp.edu.ar

The aim of the present study was to carry out histochemical analyses of the abductor muscles of *Cynoscion guatucupa*. Several histochemical techniques were used: Succinic dehydrogenase (SDH), periodic acid Schiff (PAS), Sudan Black and Red, Phosphorylase (PhR) and myosin-adenosinotriphosphatase (mATPase). In the abductor superficialis, two zones were determined: proximal and distal to pectoral girdle. Three types of muscle fibers -red, pink and white- were present in the distal zone, whereas only white fibers were present in the proximal zone. The red fibers had small diameter, presented a large number of capillaries, were intensely stained by SDH and PAS, and exhibited low activities to mATPase after acid and alkaline preincubations. The pink fibers were a mosaic with moderate reaction to SDH and PAS, stable mATPase activities to acid and alkaline pHs and a moderate number of capillaries. The white fibers showed high activities to mATPase after acid and alkaline preincubations, and the smallest fibers were weak to SDH and PAS. The capillaries were scarce. None of the types of fiber reacted to Sudan or PhR. The abductor muscle of the pectoral fins of *C. guatucupa* is thus composed of red, pink and white fibers that would be involved in the fast and slow movements of swimming.

Keywords: *Cynoscion guatucupa*, muscle, histochemistry.

**DETERMINATION OF GLYCOPROTEINS IN THE
OVARIAN FOLLICLES OF *Genypterus blacodes***

PETCOFF G¹; GARCÍA A^{1,6}; BARBEITO CG^{3,6}; FREIJO R¹; PORTIANSKY E^{4,6}; MACCHIG^{5,6}; DÍAZ AO^{1,2}.

1. Departamento de Biología; 2. Instituto de Investigaciones Marinas y Costeras (IIMyC), Facultad de Ciencias Exactas y Naturales - CONICET-Universidad Nacional de Mar del Plata. Funes 3250, 3° piso, CP 7600. Mar del Plata, Buenos Aires - Argentina. 3. Cátedra de Histología y Embriología; 4. Instituto de Patología. Facultad de Ciencias Veterinarias, Universidad Nacional de La Plata, 60 y 118 s/n, CP 1900. La Plata, Buenos Aires - Argentina. 5. INIDEP. 6. CONICET.

e-mail: gpetcoff@mdp.edu.ar

Ovaries of *Genypterus blacodes* correspond to the cystovarian type, i.e. hollow organs into which numerous ovigerous lamellae project to the central lumen. The aim of this work was to analyze the composition of carbohydrates of the growing follicles of *G. blacodes*. To this end, females of *G. blacodes* were collected during two research trawl cruises carried out in San Jorge Gulf (Argentina). Samples were fixed in buffered formalin and routinely processed to paraffin wax. To localize and identify glycoproteins (GPs), the following techniques were applied: PAS: GPs with oxidizable vicinal diols; PA*S: sialic acid and some of their chain variants; KOH/PA*S: GPs with sialic acids residues; PA/Bh/KOH/PAS: sialic acids residues with O-acyl substitution and O-acyl sugars; Alcian blue pHs 2.5, 1.0 and 0.5: GPs with carboxyl groups and with sulphate esters. During the initial phase of the maturation, the small granules of vitellum observed were composed of GPs that increased gradually during exogenous vitellogenesis. Cortical alveoli showed neutral GPs and GPs bearing carboxyl groups. The zona radiata showed a positive reaction to PAS. The follicular envelope had neutral and acid GPs. In conclusion, the histochemistry composition of the oocytes of *G. blacodes* allows inferring physiological specific reproductive functions.

Keywords: *Genypterus blacodes*, ovary, histochemistry.

EXPRESSION OF CALBINDIN IN THE RED NUCLEUS OF THE RAT DURING AGING

PIOVE M¹; SILVA L¹; CAMBIAGGI V¹; GOYA R²; ZUCCOLILLI G¹.

1. Laboratorio de Neurociencias, Departamento de Ciencias Básicas, Facultad de Ciencias Veterinarias, Universidad Nacional de La Plata. Calle 60 y 118 s/n, CP 1900. 2. INIBIOLP, Facultad de Medicina, Universidad Nacional de La Plata. 60 y 120 s/n. La Plata, Buenos Aires - Argentina.
e-mail: vcambiaggi@fcv.unlp.edu.ar

Laboratory rodents (rats and mice) are a frequent neuroscience research model to study brain aging mechanisms. The red nucleus is an important nucleus of the midbrain that is involved in locomotion and control of the locomotive activity. Calbindin is a protein involved in the maintenance of intracellular calcium. Because of its high binding rate and affinity with this cation, it is considered that this protein acts as a neuroprotective buffer of fast action. In 1995, red nucleus calbindin expression was cited by Hontanilla, who identified large neurons in the caudal two thirds of the nucleus. In this study, the brains of female Sprague Dawley rats of different ages (5, 24 and 30 months) were fixed and sectioned. The sections obtained were arranged in equidistant series for processing with Nissl and immunohistochemical techniques for the calbindin D-28 KD. A significant decrease was observed in the total number of neurons in the red nucleus from 24-month-old rats. However, calbindin expression increased with age. At 5 months, 23% of the red nucleus neurons expressed calbindin, whereas at 24 months, 64% of neurons were positive and this increase was maintained (58%) to 30 months. These results may help in the search for neuroprotective therapies based on the use of endogenous molecules that promote neuronal survival.

Keywords: red nucleus, calbindin, aging.

VEGF EXPRESSION AND ITS RELATIONSHIP WITH MITOTIC ACTIVITY AND DNA SYNTHESIS DURING LIVER REGENERATION

ANDRINI L; GARCÍA MN; INDA A; ERRECALDE AL.

Cátedra de Citología, Histología y Embriología "A", Facultad de Ciencias Médicas, UNLP. Calle 60 y 120 s/n, CP 1900. La Plata, Buenos Aires - Argentina.

e-mail: landrini@med.unlp.edu.ar

Angiogenesis is mainly stimulated by vascular endothelial growth factor (VEGF) and is a fundamental requirement for liver regeneration and cell proliferation. The following experiments were designed to study VEGF expression, mitotic activity (MA) and DNA synthesis (DNAs) in adult male mice during liver regeneration. We used C3H/S adult male mice, which were killed every 4 hours from 26 to 50 hours posthepatectomy. Liver samples were processed by immunohistochemical technique for the expression of VEGF and DNAs, and hematoxylin-eosin was used for the evaluation of MA. Indices were established as $X \pm SE$ for each lot and each group. For the statistical analysis, we used ANOVA and Tukey's post-test. The maximum value of DNAs in mice was found at 16/30 (time day/hours posthepatectomy), followed by the maximum value of VEGF expression, which occurred at 8/46. The maximum value of MA was observed at 12/50. On the other hand, the minimum values for MA were observed at 20/34, those for DNAs at 00/38 and those for VEGF expression at 12/50. We concluded that during liver regeneration, hepatocytes react by synthesizing DNA, and then expressing VEGF, to ensure the formation of a vascular bed proper and sufficient for the nutrition of daughter cells.

Keywords: VEGF, cellular proliferation, liver regeneration.

**ANALYSIS OF THE HYPERPLASTIC COMPONENT OF TUBULAR EPITHELIAL CELLS
DURING EARLY COMPENSATORY RENAL GROWTH**

BLANCO MD; DOMÍNGUEZ MAGADÁN PA; RODRÍGUEZ EM; FERNÁNDEZ BLANCO A; GARCÍA AL; ERRECALDE AL.

Cátedra de Citología, Histología y Embriología "A", Facultad de Ciencias Médicas, UNLP. Calle 60 y 120 s/n, CP 1900. La Plata, Buenos Aires - Argentina.

e-mail: algarcia@med.unlp.edu.ar

This work, which is part of a more extensive project, aimed to analyze the hyperplastic component through the mitotic activity of tubular cells in the cortex and outer medulla of the kidney of adult mice of both sexes, at 20:00/10 hour day/hours post-uninephrectomy. To this end, 12 male and 12 female 90-day-old mice were used. Mice were standardized for periodicity analysis and divided into two groups: uninephrectomized (Nx) and sham-operated (FNx). The operations were performed under anesthesia with Ketamine (100 mg/kg, ip) and Diazepam (10 mg/kg, ip). Four hours before sacrifice, a solution of 0.01 ml by gram of corporal weight of colchicin was injected ip. The right kidney extracted was processed by routine technique for histology. In each sample, mitosis was recorded in 3000 nuclei of proximal convoluted and straight tubules. The results are expressed as index of mitotic activity for each animal and as $X \pm \text{ESM}$ (Mean \pm Standard Error of the Mean) (n) for each group and statistically analyzed with the Student's "t" test or ANOVA. We observed no significant differences between the treatments in the zones analyzed or between sexes within a same treatment. We concluded that at 10 hours post-uninephrectomy, compensatory renal growth does not present a hyperplastic component in adult mice.

Keywords: kidney, mitotic activity, mice.

DNA SYNTHESIS IN LIVER CELLS OF YOUNG INTACT AND HEPATECTOMIZED TUMOR-BEARING ES2 MALE MICE

FERNÁNDEZ BLANCO A; INDA AM; ERRECALDE AL.

Cátedra de Citología, Histología y Embriología "A", Facultad de Ciencias Médicas, UNLP. Calle 60 y 120 s/n, CP 1900. La Plata, Buenos Aires - Argentina.

e-mail: ayelenfblanco@yahoo.com.ar

Previous studies have demonstrated the existence of a circadian rhythm in DNA synthesis (DNAs) in hepatocytes from male mice. The aim of this paper was to analyze DNAs in intact young animals, hepatectomized and hepatectomized tumor-bearing mice. CH3/S male mice (28-day-old) were used, inbred and standardized for analysis of periodicity. They were divided into intact (non-operated), hepatectomized and hepatectomized ES2 tumor-bearing groups and each group was divided into lots (n = 6) which were sacrificed at 00, 04, 08, 12, 16 and 20 h (intact mice) and 12/26, 16/30, 20/34, 00/38, 04/42 and 08/46 hours a day/hour post-hepatectomy (HD/HPH) (hepatectomized and hepatectomized tumor-bearing mice), after injection of 5-bromodeoxyuridine 1 h before. Liver samples were subjected to coloring techniques of H & E and immunohistochemistry for the determination of the nuclei in synthesis. Observation of cells was analyzed at 100x and 1500 periportal and perivenular hepatocytes per animal were counted. The $\bar{X} \pm \text{SEM}$ (Mean \pm Standard Error of the Mean) was calculated for each lot and differences between groups were statistically analyzed with the Student's t-test, ANOVA and a post-test. Values peaked at 08 and 12 h in intact mice, at 20/34 and 00/38 HD/HPH in hepatectomized mice and at 12/26 HD/HPH in hepatectomized tumor-bearing mice. We conclude that young male mice possess temporal variations in their DNAs and that the maximum value is advanced and increased in tumor-bearing animals.

Keywords: liver, circadian rhythm, bromodeoxyuridine.

**APOPTOTIC AND PROLIFERATIVE ACTIVITY IN PLACENTAS OF
CHRONICALLY STRESSED RATS**

COTS DS; ROLANDO AN; DÍAZ T; MUGNAINI MT; SOÑEZ CA; BOZZO A; GAUNA HF; ROMANINI MC.

Laboratorio de Biología Celular y Embriología, Dpto. Anatomía Animal, Facultad de Agronomía y Veterinaria, Universidad Nacional de Río Cuarto. Ruta Nac. 36, km 601, CP 5800. Río Cuarto, Córdoba - Argentina.

e-mail: deboracots@gmail.com

Chronic stress during gestation can alter several mechanisms that maintain homeostasis in the placenta. The aim of this study was to determine cell proliferation and apoptosis in placentas of chronically stressed rats. Control and stressed rats were used. Stress by immobilization was applied on days 12, 17 and 21 of pregnancy. Placental sections were immunolabeled with anti-BrdU (to evaluate proliferation) and TUNEL (to evaluate apoptosis). The apoptotic index showed no significant differences between groups, but significant differences between gestational stages. This index decreased on day 17 and, then increased on day 21. In contrast, the proliferation index presented significant differences between groups and gestational stages studied. This index increased on day 17 and then decreased on day 21. We concluded that there is a significant relationship between apoptosis and cell proliferation, two biological processes that contribute to the correct formation and normal development of the placenta, and thus to a successful pregnancy and delivery. In placentas of stressed rats, these two processes were found to be related just as in the control group. However, cell proliferation increased by stress effects. Also, one can speculate that the chronic stress applied to mothers can generate a deleterious environment for the fetus development.

Keywords: chronic stress, apoptosis, cell proliferation, placenta.

**PRELIMINARY STUDY OF STRUCTURE AND CELLULAR REMODELING BY
APOPTOSIS IN GOAT PLACENTAS**

DÍAZ T^{1,3}; MERKIS CI²; CRISTOFOLINI AL²; SANCHIS EG^{2,3}; COTSDS^{1,3}; ROMANINI MC¹; ROLANDO AN¹.

1. Laboratorio de Embriología, Dpto. de Anatomía Animal. 2. Área de Microscopía Electrónica, Dpto. Patología Animal, Facultad de Agronomía y Veterinaria, Universidad Nacional Río Cuarto. 3. Becario CONICET/MinCyTCba. Ruta Nac. 36, km 601, CP 5800. Río Cuarto, Córdoba - Argentina.

e-mail: tdiazvet@gmail.com

In most mammals, apoptosis is a highly regulated process essential for normal development and differentiation of most tissues, including the placenta. The goat has a synepitheliochorial, cotyledonary and semideciduous placenta. So far, there is no evidence describing the apoptotic phenomenon in goat placentation. The aim of this work was to carry out a preliminary study of the cellular remodeling by apoptosis in the placentas of goats throughout gestation. Placentas were processed at 50 days of gestation (n = 5), 100 days of gestation (n = 5) and at term (n = 5). Placental samples were fixed in 10% formalin, dehydrated, embedded in paraffin and histological sections of $\pm 4.5 \mu\text{m}$ were obtained. Some of the sections were stained with hematoxylin-eosin and Masson's trichrome for structural analysis by optical microscopy and other sections were allocated to the study of DNA fragmentation by the TUNEL technique (Apoptag®). The histological structure of the trophoblast epithelium of the placentomes showed mononuclear cells alternating with binucleate cells, and was found to be cylindrical at the basal zone of the fetal villi, typically columnar and then modified to cubic in the apex of these villi. Apoptotic cells showed different distribution, the apoptotic index being higher in the base than at the apex of the villi. Most cellular remodeling by apoptosis in goat placentation was observed in placentas at term. We concluded that it is an essential process for the preparation for delivery.

Keywords: placenta, apoptosis, goat.

HISTOLOGICAL AND HISTOCHEMICAL STUDY OF THE DUODENUM OF FETUSES OF THE PLAINS VISCACHA (*Lagostomus maximus*)

TANO DE LA HOZ MF^{1,2}; FLAMINI MA³; DÍAZ AO².

1. Comisión de Investigaciones Científicas (CIC). 2. Instituto de Investigaciones Marinas y Costeras, Facultad de Ciencias Exactas y Naturales, Departamento de Biología. CONICET. Universidad Nacional de Mar del Plata. Funes 3250, 3° Piso, CP 7600. Mar del Plata, Buenos Aires - Argentina. 3. Cátedra de Histología y Embriología, Facultad de Ciencias Veterinarias, Universidad Nacional de La Plata. Calle 60 y 118 s/n, CP 1900. La Plata, Buenos Aires - Argentina.

e-mail: mftano@mdp.edu.ar

The objective of this work was to carry out a histological and histochemical analysis of the duodenum of mid-term and at-term gestation fetuses of *Lagostomus maximus*. Duodenal samples were taken at approximately 1 cm from the pylorus. Histological techniques, histochemical techniques (PAS, KOH/PA*S, PA/Bh/KOH/PAS, KOH/PA*/Bh/PAS, AB pH 2.5, 1.0 and 0.5, AT pH 5.6 and 4.2) and lectin histochemical techniques were used. The duodenum of mid-term gestation fetuses presented short villi covered by a simple undifferentiated cubic epithelium, while the duodenal mucosa of at-term fetuses was lined by a simple cylindrical epithelium with goblet cells. Only fetuses at term presented Lieberkühn glands. The tunica submucosa of at-term fetuses had Brunner glands. The tunica muscularis was formed by a single circular layer in the mid-gestation fetuses and two concentric layers in at-term fetuses. The duodenal histochemical profile was similar in both fetal stages. Only fetuses at mid-gestation showed PAS-positive granules in both enterocytes and in the traces of Lieberkühn glands. The lectin histochemical techniques allowed identifying different residues of monosaccharide sugars evident in the glycoproteins (GPs). The histochemical techniques revealed that GPs in the duodenum of *L. maximus* as well as their glycosylation patterns vary according to the animals' age.

Keywords: *Lagostomus maximus*, duodenum, ontogenetic development.

**INSULIN-LIKE GROWTH FACTOR 2 (IGF2) AND IGFR1 EXPRESSION
IN CANINE AND FELINE PLACENTAE**DIESSLER ME¹; BARBEITO CG^{1,2}; ORTEGA HH^{2,3}; REY F^{2,3}.

1. Cátedra de Histología y Embriología, Facultad de Ciencias Veterinarias, Universidad Nacional de La Plata. Calle 60 y 118 s/n, CP 1900. La Plata, Buenos Aires - Argentina. 2. Consejo Nacional de Investigaciones Científicas y Técnicas (CONICET). 3. Departamento de Ciencias Morfológicas, Facultad de Ciencias Veterinarias, Universidad Nacional del Litoral. Esperanza, Santa Fe - Argentina.
e-mail: monicadiessler@gmail.com

Insulin-like growth factors (IGFs) are involved in several cellular processes such as migration of trophoblast cells. In haemochorial placentae, IGFs and IGFRs expression was reported in both maternal and fetal tissues. The aim of the study was to analyze the expression of IGF2 and IGFR1 in the endotheliochorial placenta of canines and felines. Placental tissues from three dogs and one cat were processed for immunolabelling. Anti-IGF2 (1/500, Novozyme Gropep, PAC1) and anti-IGFR1 (1/300, Santa Cruz Biotechnology, sc-712) were used as primary antibodies. Detection system consisted of a secondary biotinylated antibody and a streptavidin-peroxidase label. The chromogen used was 3,3' diamino benzidine. In canine samples, IGF2 was detected in fetal endothelium (mature placentae), mesenchyma, cytotrophoblast (early placentae), syncytiotrophoblast and maternal blood and endothelium. Besides, endometrial gland epithelium (apical and basal regions of the cells) and cells of the connective axis of the glandular tubes showed also positive reaction. Among the features of feline placenta labelling, it is interesting to point out that decidual cells strongly reacted to IGF2 antibody. IGFR1 was detected in fetal endothelium, mesenchyma and basolateral domain of the glandular epithelium plasma membrane. Maternal endothelium and connective tissue were poorly stained. IGF2 was expressed in trophoblastic cells of carnivores, especially during early placentation, whereas it was not detected in species developing less invasive placentae. Later expression in foetal endothelium is probably related to labyrinth remodelling. In these species the placenta is also under circulating IGF2 control. Coexpression of ligand and receptor in some populations supports the existence of autocrine signalling for this system in carnivore placentae.

Keywords: endotheliochorial placenta, IGF, immunohistochemistry.

REPRODUCTION OF *Solidago chilensis* (ASTERACEAE), AN ORNAMENTAL NATIVE SPECIES FROM CÓRDOBA (ARGENTINA)REYNA ME¹; GIL SP¹; SEISDEDOS L¹; ARGÜELLO I²; CERANA MM¹.

1. Botánica Morfológica. 2. Laboratorio de Semillas. Facultad de Ciencias Agropecuarias, Universidad Nacional de Córdoba. Ciudad Universitaria s/n, CP 5000. Ciudad de Córdoba, Córdoba - Argentina.

e-mail: mreyna@agro.unc.edu.ar

Solidago chilensis Meyen “vara de oro” (Asteraceae-Astereae) is a beautiful perennial rhizomatous herb with simple leaves. It has compound racemes (panicles) of yellow capitula with dimorphic flowers. The aim of this study was to analyze the reproductive capacity of this native plant to be introduced in the ornamental market. The material was obtained from populations which grow in La Calera, Córdoba, Argentina. The germination assays were carried out in the Seed Laboratory (FCA-UNC) with achenes collected between 2008 and 2011, scarified and non-scarified. The assays were carried out in triplicate with 50 fruits each (for treatment and for year). For the vegetative propagation, 30 cuttings of the rhizomes were used for each treatment, with or without powdered rooting hormone, collected in 2011 with the substrate of the place where the plants grow. The results were studied with analysis of variance and compared with Fisher’s LSD method. The germination percentage oscillated between 12 and 88 % and there were no significant differences between treatments, but significant ones between years of crops (2008 vs. the others). Germination is phaneroepigeal. The seedlings presented cotyledons ovate with entire margins and their shapes were similar to the first nomophylles. The survival of the seedlings was poor. On the other hand, 90% of the cuttings originated normal plants without significant differences between treatments, and were transplanted successfully. For this reason, we considered that this is the best way for its cultivation as an ornamental plant.

Keywords: Asteraceae, germination, cuttings.

**DIAGNOSTIC LEAF TRAITS FOR SPECIES OF *Nothofagus* BL. (NOTHOFAGACEAE)
FOR POSSIBLE USE IN INFRAGENERIC STUDIES**

RIVERA SM¹; SÁENZ AA²; VILLARREAL M¹; DUNCAN M¹.

1. Departamento de Dendrología, CIMAD, Facultad de Ciencias Agrarias y Forestales, Universidad Nacional de La Plata. 2. Cátedra de Morfología Vegetal, Facultad de Ciencias Naturales y Museo, Universidad Nacional de La Plata. Paseo del Bosque, CP 1900. La Plata, Buenos Aires - Argentina.

e-mail: stellarivera08@gmail.com

The *Nothofagus* genus comprises about 35 species distributed in the Southern Hemisphere, nine of which grow in the Southern Cone of America and three in Tasmania and Australia. The aims of this study were to extend and complement the existing descriptions regarding cuticular morphology and cross section of leaves of the species mentioned, and to establish diagnostic value traits that allow the determination of possible natural hybrids. The material used was herbal material and fresh material fixed in Formalin-Acetic acid-Alcohol, and subsequent treatment and inclusion in paraplast safranin-fast green staining for observation with optical and standard techniques for scanning electron microscope observation. The selected characters were: cuticle thickness, type of garment, arrangement of stomata, epidermal model, type of vascular bundle, and percentage and type of chlorenchyma.

Keywords: leaf morphology, *Nothofagus*, hybrids.

Plantago bismarckii NIEDERL (PLANTAGINACEAE) WITH ABSENCE OF RAYS.
ENDEMISM IN BUENOS AIRES, ARGENTINA

RIVERA SM¹; CABANILLAS PA²; BORNIEGO ML²; SÁENZ AA².

1. Departamento de Dendrología, CIMAD, Facultad de Ciencias Agrarias y Forestales, Universidad Nacional de La Plata. 2. Cátedra de Morfología Vegetal, Facultad de Ciencias Naturales y Museo, Universidad Nacional de La Plata. Paseo del Bosque, CP 1900. La Plata, Buenos Aires - Argentina.

e-mail: stellarivera08@gmail.com

Plantago bismarckii is endemic in the Western (Puan, Curamalal, Bravard and Ventana) and Southern mountain Systems (Ventania) of Argentina, between 500 and 1000 m. This morphostructural unit like northern highlands (Tandilia) emerges as islands in the plains and low undulating terrain surrounding the pampas. The *Plantago* genus comprises about 270 species, most herbaceous ones. *Plantago bismarckii* is a nanophanerophyte up to 0.8 m in height, stems going upwards and forming a hemispherical cup of approximately 1 m in diameter, which grows on rocky outcrops in discrete units. The xylologic features observed were: demarcated growth rings, diffuse-porosity, vessels solitary circular to oval outline, simple perforation plate with pits and inclined circular ridge opposite to alternate, circular outlined fibers with fiber lumen small, square outlined fibers with fiber lumen broad, tracheids quadrangular section, amorphous substances present, partial layered structure (vessel elements and tracheids), rays absent. It is considered that the absence of rays is a case of pedomorphism where characters of the primary xylem are present in the secondary xylem. The features observed are related to those described by other authors for woody island representatives. This "insular woodiness" is the tendency of some species, of the same genus, to be woody on islands and herbaceous on the continent.

Keywords: *Plantago bismarckii* Niederl, pedomorphism, Ventania.

MORPHOLOGY OF LEAF GALLS IN *Schinus longifolius* (LINDL.) SPEG. (ANACARDIACEAE)
OF THE BIOTA OF THE RÍO DE LA PLATA RIVER (ARGENTINA)

KUZMANICH N; SÁENZ AA.

Cátedra de Morfología Vegetal, Facultad de Ciencias Naturales y Museo, UNLP. Paseo del Bosque s/n, CP 1900. La Plata, Buenos Aires - Argentina.

e-mail: nkuzmanich_twch@yahoo.com.ar

Galls or cecidia are structures that develop in a plant in response to the specific activity of an organism, which generally is an insect, but not excluding other taxa such as viruses, bacteria, mites, etc. In order to be considered galls, they must include hypertrophy and hyperplasia phenomena. *Schinus longifolius* is distributed from southern Brazil, Paraguay, Uruguay, and northeastern Argentina. In Argentina, it grows on the banks of the Paraná River and the coastal forests east of the province of Buenos Aires. The material studied was collected on the coast of the La Plata river, fixed in FAA, included in Paraplast to obtain histological sections, stained with safranin-fast green and mounted using synthetic mounting media. For classification, we followed Mani (1964). Three morphological types were recognized: two of them belonging to the pouchgall group: A- spherically shaped and green, developing on the adaxial side of the leaf blade; B- conical and reddish, developing on the abaxial surface, and the third type belonging to the type of rolling galls: the rolling up of these galls occur from the apex of the leaf toward the center of it in abaxial sense.

Keywords: galls, morphology, *Schinus longifolius*.

DEVELOPMENT OF CAMBIAL VARIANTS IN *Serjania meridionalis* CAMBESS (SAPINDACEAE: PAULLINIEAE) OF MARTIN GARCIA ISLAND (BUENOS AIRES, ARGENTINA)

BORNIEGO ML; CABANILLAS PA; SÁENZ AA.

Cátedra de Morfología Vegetal, Facultad de Ciencias Naturales y Museo, UNLP. Paseo del Bosque s/n, CP 1900. La Plata, Buenos Aires - Argentina.
e-mail: luborniego@hotmail.com

Different types of cambial variants, also called "anomalous secondary growth", have systematic importance. This type of secondary growth is very common in lianas, and is important for its study. Despite the abundance and distribution of climbing plants, anatomical studies on their secondary xylem are still scarce. Most studies have focused on the description of mature cambial variants, and thus their development is usually not taken into account. Sapindaceae is one of the most important families of climbers of tropical America. The members of the tribe Paullinieae, which groups all representative climbers, have stems with highly specialized and unique structures. The genus *Serjania* is one of the largest and most widely distributed one, being *Serjania meridionalis* the southernmost species, reaching the province of Buenos Aires in Argentina. Plants were serially sectioned with a microtome at different heights of the stalk and analyzed by light microscopy. The stem is organized in cordate xylematic masses, a larger central and peripheral lower 3 to 6. In the early stages of development, a "normal" cambium, which produces secondary phloem centrifugally and secondary xylem centripetally, results in a continuous cylinder. The cambial variant starts to develop when the stem reaches at least 1 cm in diameter. New circular cambium is produced from cortical parenchyma, which forms the peripheral xylematic masses. This new cambium acts similarly to the central cambium.

Keywords: lianas, cambial variant, *Serjania meridionalis*.

**METHODS OF QUANTITATIVE AND QUALITATIVE STUDIES
OF BONE TISSUE**

GUTIÉRREZ C; GRAUER K; BERRUELA S; GONZÁLEZ ME.

Facultad de Odontología, UdelaR. Carlos Crocker 2586, CP 12000. Montevideo, Uruguay.

e-mail: carguti.19@gmail.com

Here, we present different study methods for quantitative and qualitative assessment of bone tissue. Bone Histomorphometry, which allows the analysis and quantification of dynamic and static parameters of bone tissue, is applied in normal bone histology and bone dynamics (modeling and remodeling). Static Bone Histomorphometry enables the study of: trabecular volume, area, osteoid thickness, surface resorption, and cell quantification, whereas Dynamic Bone Histomorphometry reveals changes during time periods which can be measured by the researcher. Different substances that settle on mineralization fronts are used as marker elements. Bone densitometry, i.e. the measurement of bone calcium density, is usually measured by DEXA (Dual Energy X-ray Absorptiometry). Its application includes assessing bone segments for research and/or therapeutic purposes. We here systematized the different study methods that are essential for decision making in each of the areas in which we operate around the bone tissue.

Keywords: bone tissue, quantitative studies, qualitative studies.

SURFACE TENSION IN THE ENDODONTIUM

SAPIENZA ME; LUBRETO A; VARELA JN; JARA ORTIZ M; ETCHEPARE AP; SANTANGELO GV.

Asignatura Endodoncia, Facultad de Odontología, Universidad Nacional de La Plata. Calle 50 e/ 1 y 115, CP 1900. La Plata, Buenos Aires - Argentina.

e-mail: juliv2008@hotmail.com

The aim of this study was to determine which of four irrigation fluids has lower surface tension, and therefore, greater penetration into the root canal. To this end, we investigated the power of capillary penetration of root canal irrigants according to their surface tensions. Forty teeth were taken and divided into four subgroups, implementing through size 60. Each group was irrigated profusely with one of the irrigation fluids selected. All teeth were sectioned and the irrigant penetration was assessed. We observed that the irrigation fluid that first reached the cemento-dentinal junction (CDJ) by capillarity was chlorhexidine digluconate from the root canal file N°15. In decreasing order, the solutions that next reached the CDJ were EDTA (20 gauge), sodium hypochlorite (size 35) and H₂O₂ (size 55). We concluded that H₂O₂ and sodium hypochlorite do not reach the CDJ, that EDTA is highly recommended and that, from the physical point of view, chlorhexidine is the most appropriate to irrigate and that it is also a strong antiseptic.

Keywords: aids, surface tension, capillarity.

ENDODONTIC LENGTH DETERMINATION

SAPIENZA ME; ZARACHO OH; JARA ORTIZ M; SANTANGELO GV; VARELA JN.

Asignatura Endodoncia, Facultad de Odontología, Universidad Nacional de La Plata. Calle 50 e/ 1 y 115, CP 1900. La Plata, Buenos Aires - Argentina.
e-mail: juliv2008@hotmail.com

The objective of this work was to determine which technique is more effective to determine the length of the endodontium in the clinical treatment. To this end, we selected 120 pieces, divided them into three groups, and gave each group a different technique: presumptive digital, conventional X-ray and pagers. The first group was studied with smooth lime type "K" 15 gauge, the second task with equal power X-ray, and the third with ProPex II Apex Locator. Results from the digital X-ray were not relevant, whereas those from the traditional X-ray were relevant but had the disadvantage of irradiating the patient and the dentist. The electronic method ProPex II gave accuracy rates ranging from 87 to 96.5% and had the advantage of avoiding the irradiation of both the patient and the practitioner.

Keywords: radiograph, endodontium, effectiveness

DISINFECTANTS IN ENDODONTICALLY TREATED TEETH

LUBRETO A; SANTANGELO GV; VARELA JN; ZARACHO OH; SAPIENZA ME; JARA ORTIZ M.

Asignatura Endodoncia, Facultad de Odontología, Universidad Nacional de La Plata. Calle 50 e/ 1 y 115, CP 1900. La Plata, Buenos Aires - Argentina.

e-mail: juliv2008@hotmail.com

The infection of the dental pulp and periapical tissues depends largely on the bacteria affecting them, so it is necessary to know the conditions which allow the microorganisms to survive and prevail within the root canal system and its environment and thus improve the clinical criterion in the treatment of pulpal infection and regions of influence. This aim of this study was to analyze the efficiency of disinfection of the root canal system in teeth, regardless of sex or age of the patient, with different topographic anatomy in root canals. To this end, we compared the efficiency of disinfection of sodium hypochlorite, hydrogen peroxide and chlorhexidine. Culture samples of different microorganisms were made. We found that germs can colonize areas inside the root canal in which the obturation technique was able to close tightly. Although we observed that the dye passed through the canal, it does not mean that the bacteria have colonized the region. Another type of colonization analysis will be performed in future studies.

Keywords: ecology, root canals, periapical tissues.

ANALYSIS OF THREE ENDODONTIC SEALER

ZARACHOOH; JARA ORTIZ M; SAPIENZA ME; VARELA JN; LUBRETO AP.

Asignatura Endodoncia, Facultad de Odontología, Universidad Nacional de La Plata. Calle 50 e/ 1 y 115, CP 1900. La Plata, Buenos Aires - Argentina.

e-mail: juliv2008@hotmail.com

One of the greatest difficulties in seeking successful endodontic therapy is to achieve sealing of the canal through an ideal sealer. Today we continue looking for a sealer that meets all the requirements expected. The aim of this work was to comparatively study the sealing of the entire canal through transparent techniques. To this end, we used thirty single-rooted teeth which underwent conventional endodontic treatment, divided into three groups: Group 1 sealed with Grossman cement, Group 2 sealed with CPM Sealer Cement and Group 3 sealed with Cement Roeko Seal. Then the parts were subjected to a transparent process to visualize the leakage power and run off of each material. The comparative statistical results showed that Roeko Seal sealer was the best endodontic sealer of the three used in this work.

Keywords: sealing. hermetic. transparent

FILLING OF CURVED CANALS: TECHNIQUES

LUBRETO A; SAPIENZA ME; SANTANGELO GV; VARELA JN; BURNS MJ; MENTA G.

Asignatura Endodoncia, Facultad de Odontología, Universidad Nacional de La Plata. Calle 50 e/ 1 y 115, CP 1900. La Plata, Buenos Aires - Argentina.

e-mail: juliv2008@hotmail.com

The aim of this study was to study different root canal filling techniques. Root canals are complex systems due to their particular anatomy. Conventional sealing techniques using gutta-percha and cement could be used in curved canals or certain curvatures but not so in very curved canals because of the difficulty to use the instruments and equipment correctly. Thus, new sealing techniques, which consist of using thermoplastic softened gutta-percha with sealers and/or cements, have arisen. The most frequently used instruments are guns as calibrated shutters. The biggest problem is to obtain a sealing technique that meets all the requirements: being three dimensional, permanent and far-reaching. We present the different obturation techniques with thermoplastic material used in curved canals. The new thermoplastic sealing techniques allowed sealing curved ducts that were previously impossible to seal.

Keywords: shutter, curvatures, materials.

ENAMEL WITH HUNTER SCHREGER BANDS AND ITS RELATIONSHIP TO OCCLUSION IN DECIDUOUS TEETH

TANEVITCH A; DURSO G; LLOMPART G; BATISTA S; ABAL A; LICATA L; LLOMPART J; MARTÍNEZ C; GREGORUTTIR; PÉREZ P.

Facultad de Odontología, Universidad Nacional de La Plata. 50 e/ 1 y 115, CP 1900. La Plata, Buenos Aires - Argentina.

e-mail: atanevitch@yahoo.com.ar

Articulation of teeth starts with the eruption of primary incisors. Posterior primary teeth occlude in such a way that a mandibular cuspid articulates in front of its upper counterpart to end on a flush terminal plane. Incisors are vertically positioned with minimum overjet and overbite, and occlusal surfaces appear largely ground. Deciduous enamel is half as thick as permanent enamel and tends to be uniform. Hunter-Schreger bands run from the amelodentinal junction towards the outer surface, without reaching it, and prisms in a band run in an opposite direction to adjacent bands originating intercrossings. Bands both strengthen the enamel and prevent fracture propagation. The purpose of this work was to establish the relationship between band thickness and the total thickness of enamel in anterior primary teeth. Vestibular-lingual sections of crowns of primary anterior teeth were exfoliated, epoxy-resin embedded, ground and polished. Twenty-four measurements of band thickness and of the total thickness of the enamel in the medial and incisal zones were carried out. The average of enamel thickness was 405.70μ (SD= 151.41μ) and band thickness was 292.28μ (SD= 104.19μ). The proportion of bands was 0.72. We concluded that the presence of bands in the deciduous enamel represents, in average, nearly 3/4 of the total thickness, thus constituting strengthening microstructures that withstand the tensional forces of fracture.

Keywords: enamel, occlusion, primary teeth.

PROPORTION OF ENAMEL WITH HUNTER SCHREGER BANDS IN TEMPORARY
AND DECIDUOUS TEETH

TANEVITCH A; DURSO G; LLOMPART G; BATISTA S; ABAL A; LICATA L; LLOMPART J; MARTÍNEZ C;
GREGORUTTIR; PÉREZ P.

Facultad de Odontología, Universidad Nacional de La Plata. 50 e/ 1 y 115, CP 1900. La Plata, Buenos Aires - Argentina.

e-mail: atanevitch@yahoo.com.ar

Tooth enamel is the mineralized tissue responsible for withstanding the forces generated by the muscular contractions of the stomatognathic system acting both in physiological (mastication and deglutition) and in pathological (tightening and bruxism) functions. The main force is exerted on the first molar and the lesser force is exerted on the incisors, the contact of which is called contact point in permanent teeth. However, the deciduous incisors contact strongly producing overjet and overbite. Prism intercrossing is a factor that would increase enamel resistance to fractures and can be identified in the Hunter Schreger band enamel. The purpose of this work was to establish the relationship between the proportion of enamel with bands and the total thickness of permanent and deciduous anterior teeth. Vestibular-lingual sections of epoxy resin-embedded, polished and etched crowns were used. Software incorporated to the scanning electron microscope was used to record the vestibular and palatine faces in the medial and incisal third. The average enamel thickness was 405.70 μ (SD= 151.41 μ) in deciduous teeth and 735.75 μ (SD=274.02 μ) in permanent teeth, while band thickness was 292.28 μ (SD=104.19 μ) in deciduous teeth and 475.03 μ (SD=184.86 μ) in permanent teeth. The proportion of bands was 0.72 in deciduous and 0.64 in permanent teeth. We concluded that the presence of bands in deciduous enamel represents, in average, nearly 3/4 of the total thickness and nearly 2/3 in permanent teeth, as a consequence of the tensional forces exerted on the enamel.

Keywords: enamel, occlusion, Hunter-Schreger bands.

HUMAN DENTAL ROOTS: HISTOLOGICAL DIFFERENCES BETWEEN APICAL CEMENT AND PEARLS

KOHLI A¹; PEZZOTTO SM²; POLETTO L².

1. Facultad de Odontología. 2. Consejo de Investigaciones. Universidad Nacional de Rosario. Calle Santa Fé 3160, CP 3100. Rosario, Santa Fé-Argentina.

e-mail: aliciakohli2009@hotmail.com

To support a dental piece in occlusion, the secondary cement is deposited in the apex. After an extraction or by X-ray photography, non-apical cement can be detected, with a hard oval or rounded pearl shape. In this work, we compared the histological structure of pearl cement with that of normal roots. Twenty teeth with pearls (G1) and twenty with normal roots (G2) were cut transversely. The pearls were cut to the half and the roots in the average part of the third apical, and the following variables analyzed: age, tooth group, diseases and periodontal diseases previously recorded, lagoons and quantity and disposition of canaliculi. Proportions were calculated between pearls and roots by tests chi-square, Fisher's exact test, significance at 5%. Mean age was 61 ± 16 in G1 and 55 ± 18 in G2 ($p=0.289$). In G1, there was a higher proportion of right upper posterior teeth and in G2 a higher proportion of right anterior and posterior teeth. Other diseases were suffered by 55% of G1 and 70% of G2, whereas 10% of G1 and 35% of G2 presented periodontal disease. Lagoons were numerous in 50% of G1 and scanty in 95% of G2 ($p=0.001$), with a disordered disposition in 89% of G1 and an ordered disposition in 100% of G2 ($p<0.001$). Canaliculi were not visible at low magnification in 100% of G1 and 20% of G2 ($p<0.001$). In G1, the mean age was higher, upper posterior right teeth predominated, a lower number of general pathology and periodontal disease was detected, abundant and disordered lagoons were visualized, and canaliculi were not visible at low magnification.

Keywords: cement pathology, lagoons, canaliculi.

**INCIDENCE OF CARIES IN THE FIRST PERMANENT MOLAR IN A CHILDREN
POPULATION OF ELEMENTARY SCHOOL**

ARMENDANO A; CRIMALDI D; OBIOLS C; PALEO M; RASSÉ N; MONGHELLI H; SUÁREZ S; SERRANO V;
PILONEL; GOYA A.

Collaborators: MEDINA L; QUINTEROS J; CORONA A; PÉREZ V.

Facultad de Odontología, UNLP. Calle 50 e/1 y 115, CP 1900. La Plata, Buenos Aires - Argentina.

e-mail: armendanoalejandro@yahoo.com.ar

The first permanent molar begins to develop in the last months of intrauterine life. Its eruption in the mouth occurs at 5 years of age behind the second temporary molar without replacing any dental piece. The first permanent molar is extremely important in dental occlusion and masticatory function. Its complex anatomy makes it more capable for food retention. The lack of oral hygiene, a rich diet in carbohydrates, the presence of microorganisms, a capable host and the time factor contribute to initiating the development of caries. There were observed pupils of 1° to 6° form of the school N°120, Herminia Brumana (La Plata, Argentina) considering the use of dental brush, tooth brushing frequency, type of food, moments of sugar and number of annual visits to the dentist. The first group of 40 pupils (1° to 3° form) consisted of 22 girls, eight of which presented caries, and 18 boys, 10 of which presented caries. The second group of 60 pupils (4° to 6° form) consisted of 32 girls, 14 of which presented caries, and 28 boys, 19 of which presented caries. We determined that the higher incidence of caries was given in the second group of children, whose ages ranged between 9 and 11 years. Being the most frequent reason the lack of mouth hygiene and scanty motivation of the same ones.

Keywords: caries, molar, hygiene.

**ANALYSIS OF TOOTH ENAMEL BIOPSIES CARIOSTATICALLY
TREATED BY SPECTROPHOTOMETRY**

BASAL R; BUTLER T; LAZO G; LAZO S; ESCUDERO E; FRISO E; VISCOVICK C; POLLICINA L; PAZOS F; BELLONI F; MERLO D.

Asignatura de Histología y Embriología, Facultad de Odontología, UNLP. Calle 50 e/1 y 115, CP 1900. La Plata, Buenos Aires - Argentina.
e-mail: fedejunior1@hotmail.com

Several researchers have pointed out the importance of the spectrophotometer as an auxiliary method to observe the penetration of fluorine into the surface layers of enamel, by passing infrared light. The aim of this study was to analyze cariostatic absorption in the enamel indirectly by spectrophotometry. To this end, 40 permanent molars of adults of both sexes between 25 and 45 years old were sampled and enamel biopsies were obtained by acid attack following the technique established by De la Cruz *et al.* in 1992 to determine part conditions before treatment. These were then subjected to the action of two cariostatic treatments: 20 were treated with sodium fluoride mouthwash as 0.05% daily (group I) and 20 with thixotropic gel 1.23% pH 3.5 (group II). Biopsies were taken after treatment and analyzed with infrared light spectrophotometry. The results showed that 90% of group I and 100% of group II showed absorption of the solution. In conclusion, the spectrophotometer was able to record the entry of the cariostatic agent in both cases, but not the amounts. Consequently, the analysis with optical microscopy and scanning electron microscopy is recommended.

Keywords: enamel biopsies, cariostatic, spectrophotometry.

INJURIES IN DENTAL PIECES WITH ENDODONTIC TREATMENTS

COLAPINTO AM; SANTANGELOGV; VARELA JN; ZARACHOOH; SAPIENZA ME; ETCHEPARE AP.

Asignatura Endodoncia, Facultad de Odontología, Universidad Nacional de La Plata. Calle 50 e/ 1 y 115, CP 1900. La Plata, Buenos Aires - Argentina.

e-mail: juliv2008@hotmail.com

The aim of this study was to determine the various treatment options for dental injuries. Dentists must be prepared to treat not only small dental injuries but also more traumatic ones such as crown fractures, broken bones, etc. The extent of the injury is influenced by the severity of the traumatic event and the use or non-use of attachment protection such as mouth guards in the case of sport accidents, or air bags or seat belts in the case of car accidents. The direction of the force applied to the teeth and supporting structures, as well as the type of impact (blunt or sharp), also determines how historical damage ensues. The quality and timeliness of initial assistance contribute to the desirable result promoting healing. Explanatory graphics were used for specific injuries that can affect the endodontium and its possible evolution. Control treatments and care are important components for successful long-term outcome. Often the long-term prognosis for a traumatized tooth relates to the response of the tooth, and hence the importance of endodontic considerations in dental trauma.

Keywords: trauma, diagnosis, treatment.

LEVELS OF ESTROGEN AND PROGESTERONE IN SALIVA OF PREGNANT ADOLESCENTS DURING THE FIRST AND THIRD TRIMESTER

TOSTISB; BAUDOJE; DOMÍNGUEZ GE; CECCHO A; DI SALVIN; ALLEGRETTI PE.

Facultad de Odontología, Universidad Nacional de La Plata. Calle 11 e/ 531 y 532 N° 28 (Tolosa), CP 1900. La Plata, Buenos Aires - Argentina.
e-mail: drabaudo@yahoo.com.ar

Pregnancy is a period of hormonal changes, during which the production of estrogen and progesterone increases greatly. In pregnant women, gingivitis manifests from the second month of gestation and peaks in the eighth. To establish whether there is a relationship between the concentration of gestational hormones in saliva and the degree of severity of gingivitis, 60 pregnant adolescents (14-19 years) were studied during the first (n=30) and third (n=30) trimester of pregnancy. Hormones in saliva were determined by radioimmunoanalysis. Saliva was collected in polystyrene tubes, it was used not stimulated saliva. The index of Mulheman hemorrhage was used to determine the degree of gum disease. In the first trimester, the levels of estradiol were 12-18 pg/ml of saliva were whereas those of progesterone 14 to 48 ng/ml saliva. On the Mulheman index: grade 0 in 12 cases (40%), and grade 1 in 18 cases (60%). In the third trimester, estradiol levels were 110 to 270 pg/ml and those of progesterone 55 to 215 ng/ml. Mulheman index: grade 0 in 9 cases (30%), and grade 1 in 21 cases (70%). The results allowed establishing that for the sample examined the findings at the gingival level match with the increase in the levels of estrogen and progesterone in saliva.

Keywords: gingivitis, estrogen, progesterone.

DESCRIPTIVE CLINICAL STUDY ON RISK FACTORS FOR ORAL CANCER

MERCADO ML; ROM MG; MICINQUEVICH S; DASCANIO G.

Unidad Hospitalaria de la asignatura Patología Clínica y Estomatológica, Facultad de Odontología, Universidad Nacional de La Plata. Calle 50 e/ 1 y 115, CP 1900. La Plata, Buenos Aires - Argentina.

e-mail: margaritalilianamercado@hotmail.com

In humans, oral cancer represents approximately 3 to 4 % of all malignant neoplasms. About 90% of the cases are oral squamous cell carcinoma (SCC). Several risk factors such as tobacco, alcohol, nutrition, genetics, and chronic traumas, contribute to the development of the disease. A descriptive retrospective study on oral cancer and the risk factors related to its occurrence was carried out on a non-probability sampling of a total of 18 patients (n=8) diagnosed in the Hospital Unit of Stomatological Clinic and Pathology in the School of Dentistry at University of La Plata (Argentina). The purpose of this study was prevention and education of the population. The variables analyzed were: age groups, gender, anatomical location, risk factors, clinical manifestations, and clinical presentation. Data were processed through descriptive statistics, contingency tables and charts. We concluded that 94.44% of the cases were SCC. The disease predominated in patients between 60 and 69 years old (33.33%). There were 15 male patients (83.33%) and the ratio of men to women was of 5:1. The tongue was the predominant anatomical location in six cases (33.33%). The risk factors recorded were tobacco (29.62%) and alcohol (18.51%). About 22.22% of the patients referred to pain as the main symptom at the moment of the consultation. The most frequent clinical manifestations were ulcers and endophytic tumors (38.89%). By knowing the risk factors, it is possible to do something about the cause-and-effect relationship of agents such as tobacco and alcohol. It is also possible to choose which patients are more likely to develop a neoplasm to act at an early stage.

Keywords: cancer, risk factors, oral cavity.

EFFECTIVENESS OF TEA GREEN IN THE PREVENTION AND TREATMENT OF THE MUCOSITIS CAUSED BY CHEMOTHERAPY

BARILARO HL; BAUDO JE.

Facultad de Odontología, UNLP. Calle 50 e/1 y 115, CP 1900. La Plata, Buenos Aires - Argentina.

e-mail: drbaudo@yahoo.com.ar

Oral mucositis is one of the most common side effects of cancer treatment. It can cause the interruption of the antineoplastic treatment, cause dose limitation, affect the quality of life and even lead to therapy failure. Patients with mucositis often have dry mouth, difficulty in swallowing, burning, tingling in the lips, pain, diarrhea, etc. The present work aimed to determine the clinical efficacy of green tea in the prevention and/or treatment of mucositis in patients with cancer undergoing chemotherapy treatment. A transverse study was conducted in oncologic patients receiving chemotherapy for 6 months at the Oncology Service of the Interzonal Hospital's neuropsychiatric patients of acute and chronic "Alejandro Korn" (La Plata, Buenos Aires). The sample was represented by 60 patients (between 50 and 60 years). Before receiving cancer treatment, all of them underwent a basic prophylactic therapy with the O'Leary index for control of bacterial plaque and brushing teaching. Groups were divided into two groups of 30 patients each: Group A were instructed mouthwashes of green tea and Group B were not (control). After the first cycle of chemotherapy, in Group A: nine patients (30%) showed no mucositis, 18 (60%) showed mucositis grade 1, and 3 (10%) showed mucositis grade 2, whereas in Group B: three (10%) had no mucositis, 17 (56.67%) showed mucositis grade 1, and 10 (33.33%) showed mucositis grade 2. The results allow establishing that green tea mouthwashes would diminish the prevalence and the degree of the mucositis caused by chemotherapy.

Keywords: mucositis, green tea, chemotherapy.

**PATHOLOGIES RELATED TO THE PERICORONAL SACK
(DENTIGEROUS CYSTS)**

DI FRANCO PL; CACCIOLA SE; CELIS Z; PRADA G; BOGO P; RICCIARDI AV; TEIXEIRA POCAS MA; TEIXEIRA POCAS CE.

Asignatura de Cirugía "A", Facultad de Odontología, UNLP. Calle 50 e/1 y 115, CP 1900. La Plata, Buenos Aires - Argentina.
e-mail: paoladifranco@hotmail.com

The maxillary bones are usually home of a great variety of pathologies, generally of the cystic and neoplastic types. These pathologies are very hard to diagnose, especially when it comes to differential diagnosis. The purpose of this work was to evaluate the frequency of the injuries whose histopathological diagnosis corresponds to odontogenic cysts. To this end, we analyzed the registry files of biopsy results (histopathological) of the subject "Surgery A" of the School of Odontology of the University of La Plata (Buenos Aires, Argentina) from the 2006-2007-2008-2009-2010 periods. All the collected data were turned into tables and statistically studied. Of a total of 189 cysts found, 52.5% were found in men, 47% in women and 0.5% was not possible to determine the sex (due to registration mistakes). In addition, 56.9% of patients with dentigerous cysts and 58.7% of patients affected with keratocysts were men ($p < 0.01$). In contrast, root cysts were found most frequently in women (55.8%) than in men ($p < 0.01$). The rest of entities showed no significant differences related to sex distribution. The results obtained show that sex has a significant association with the presence of cysts of the dentigerous and root types ($p < 0.01$). Root cysts were the injuries most frequently diagnosed in general. In contrast to the dentigerous cysts type and the odontogenic keratocyst type, the root cysts diagnosed were most frequently found in women.

Keywords: retained teeth, dentigerous, cysts.

A

ABAL A.	78, 79
ACHINELLY MF.	54
ALLEGRETTI PE.	84
ALTUNA RUIZ JE.	22
ANDRINI L.	60
ARCURI A.	49, 50
ARCURI M.	49, 50, 51
ARGÜELLO I.	67
ARMENDANO A.	81

B

BARBEITO CG.	58, 66
BARILARO HL.	86
BASAL R.	82
BATISTA S.	78, 79
BAUDO JE.	84, 86
BELLONI F.	82
BERGEL ML.	38
BERNAL V.	35
BERNARDI H.	49, 50, 51
BERRUELA S.	72
BERTANI OB.	22
BLANCO MD.	61
BOGO H.	52
BOGO P.	87
BORNIEGO ML.	69, 71
BOZZO A.	63
BRACHETTA-APORTA N.	35
BURNS MJ.	77
BUTLER T.	82

C

CABANILLAS PA.	1, 69, 71
CACCIOLA SE.	87
CAMBIAGGI V.	59
CAMINO NB.	33, 34, 40, 54
CAPRARO C.	52, 53
CAPRARO MC.	52, 53
CAPRARO ME.	52, 53
CARDOSO J.	31
CARIAGA A.	36
CARRIL J.	32
CASTRO LE.	38
CECCHO A.	84
CECHO AC.	42, 43
CELIS Z.	87

CERANA MM.	67
CESANI MF.	38, 39
CIRIMARCO C.	49, 50
COHEN S.	55, 56
COLAPINTO AM.	83
COTS DS.	63, 64
CRIMALDI D.	81
CRISTOFOLINI AL.	64

D

DASCANIO G.	85
DE CHAZAL LE.	16
DESÁNTOLO B.	36
DEVINCENTI CV.	57
DI FRANCO PL.	87
DI SALVI N.	84
DÍAZ AO.	55, 56, 57, 58, 65
DÍAZ JF.	22
DÍAZ MV.	56
DIAZ T.	63, 64
DISSLER ME.	66
DOMÍNGUEZ GE.	84
DOMÍNGUEZ MAGADÁN PA.	61
DUNCAN M.	68
DURSO G.	78, 79

E

ELICECHE D.	54
ELISSONDO M.	44
ERRECALDE AL.	37, 60, 61, 62
ESBORRAT L.	31
ESCUDERO E.	82
ETCHEPARE AP.	73, 83

F

FELIPE A.	44
FERNÁNDEZ BLANCO A.	61, 62
FIORETTI C.	46
FLAMINI MA.	65
FORTE LM.	38
FREIJO R.	58
FRISO E.	82
FUCINI MC.	39

G

PEREZ P.	78, 79
PETCOFF G.	58
PEZZOTTO SM.	80
PICASSO MBJ.	32
PIERGIACOMI VA.	41
PILONE L.	81
PINGITORE C.	44
PIOVE M.	59
PLISCHUK M.	37
POLETTI L.	80
POLLICINA L.	82
POLONI L.	46
PORTIANSKY E.	58
PRADA G.	87
PRIO V.	39

Q

QUERAL M.	31
QUINTERO FA.	38, 39

R

RASSÉ N.	81
REBOREDO GR.	41
REY F.	66
REYNA ME.	67
RICCIARDI AV.	52, 53, 87
RICCIARDI N.	52
RIVERA MC.	46
RIVERA SM.	68, 69
RODRÍGUEZ EM.	61
RODRÍGUEZ N.	46
ROLANDO AN.	63, 64
ROM MG.	85
ROMANINI MC.	63, 64
RUSCONI JM.	33

S

SÁENZ AA.	68, 69, 70, 71
SALAGOITY F.	31

SALAS A.	54
SALAS L.	34
SANBARTOLOMEO PM.	42
SANCHIS EG.	64
SANTANGELO GV.	73, 74, 75, 77, 83
SAPIENZA ME.	73, 74, 75, 76, 77, 83
SCARPINELLI L.	22
SEISDEDOS L.	67
SERRANO V.	81
SILVA L.	59
SOÑEZ CA.	63
SPALA M.	31
SPARACINO S.	52, 53
SUAREZ S.	81

T

TANEVITCH A.	78, 79
NO DE LA HOZ MF.	65
TAPIA G.	47, 48
TEIXEIRA POCAS CE.	87
TEIXEIRA POCAS MA.	87
TERRASA AM.	41
TORRES MF.	38
TOSTI SB.	42, 43, 84

V

VARELA JN.	73, 74, 75, 76, 77, 83
VARELA M.	46
VERGARA V.	34
VILLACORTA A.	44
VILLANUEVA M.	39
VILLARREAL M.	68
VISCOVICK C.	82

Z

ZARACHO OH.	74, 75, 76, 83
ZEINSTEGER PA.	41
ZONTA ML.	38
ZUCCOLILLI G.	59