

## CHRONIC OSTEOARTHRITIS IN A CAPTIVE MOUNTAIN LION (*Felis concolor*)

Briceño AM<sup>1</sup>, Garcia F<sup>1</sup>, Gómez M<sup>2</sup>, Alvizu E<sup>3</sup>, Morales I<sup>3</sup>, Chiachio N<sup>3</sup>

<sup>1</sup>Department of Veterinary Pathology. Faculty of Veterinary Science

<sup>2</sup>Faculty of Agronomic, Central University of Venezuela. Aragua State.

<sup>3</sup>Zoological Park "El Pinar", Caracas-Venezuela.

**ABSTRACT:** A 23-year-old male Mountain Lion (*Felis concolor*) died after developing chronic lameness in the Zoological Park "El Pinar", Caracas-Venezuela. Were practice euthanasia. Grossly, the radio-ulnar- humeral joint had severe bilateral lesions on the surface of the articular cartilage, with erosion of the cartilage and exposure of subcondral bone. There was approximately 1 ml of synovial fluid that was yellowish, and had a decreased viscosity. Histopathology revealed severe erosion and ulceration of the articular cartilage, with variable degrees of exposure of the subcondral bone. Bone tissue had defective osteoid matrix formation, and mineralization failure, resulting in loss of bone lamellae. Radiographic changes included decreased cortical density, trabecular growth pattern, fractures and microfractures. Failure in the formation of bone callus, and presence of osteophytes. These reports support the osteoarthritis and degenerative disease joint under conditions of captivity in a mountain lion.

**Key Words:** Osteoarthritis, Mountain lion, *Felis concolor*, pathology, articular

## OSTEOARTRITIS CRONICA EN UN LEON DE MONTAÑA (*Felis concolor*) EN CAUTIVERIO

**RESUMEN:** Un león de montaña (*Felis concolor*), macho de 23 años de edad Montaña desarrollo una claudicación crónica en el parque zoológico "El Pinar", Caracas-Venezuela. Se le practico eutanasia. Macroscópicamente, la articulación humero-radio-cubital, presento severas lesiones bilaterales en la superficie del cartilago articular, con erosión del cartilago y exposición del hueso subcondral. Aproximadamente 1 ml de líquido sinovial presento de color era amarillento y una viscosidad disminuida. La histopatología reveló una severa erosión y ulceración del cartilago articular, con grados variables de exposición del hueso subcondral. El tejido óseo presento defectuosa formación de la matriz osteoide, con fallas en la mineralización, lo que resulta en la pérdida de laminillas óseas. Los cambios radiográficos incluyen disminución densidad cortical, el patrón de crecimiento trabecular, las fracturas y microfracturas. Fallas en la formación de callo óseo, y la presencia de osteofitos. Estos resultados son consistentes con artrosis y enfermedad degenerativa que son comunes en condiciones de cautiverio en el león de montaña.

**Palabras clave:** Artrosis, puma, *Felis concolor*, patología articular.

Fecha de recepción: 06/07/11

Fecha de aprobación: 06/12/11

**Dirección para correspondencia:** Jabelardo Morales Briceño Department of Veterinary Pathology, Faculty of Veterinary Science, Central University of Venezuela, ADDRESS Maracay, Aragua State Venezuela

**Email:** aamorales13@gmail.com

## A. Moralesy col.

Osteoarthritis is a chronic degenerative disorder that is defined as the progressive degeneration of the cartilage in a joint (3, 4, 6). This noninflammatory disorder may follow a trauma or it may be a complication of malformations. Osteoarthritis affects the articular cartilages. Healthy cartilages are smooth and prevent friction when the joint surfaces rub each other. It has a cushioning effect in the joint, acting as a shock absorber during movement. In osteoarthritis, also called wear and tear arthritis, the cartilage wears off and the surfaces of the bones become rough (5). Under those conditions, friction causes pain, swelling, and loss of motion of the joint. Pieces of bones or cartilage can also break off and float in the joint space. There is also the possibility of bone spurs or osteophyte formation (2). The aim of this study was to describe osteoarthritis in a Mountain Lion (*Felis concolor*).

A 23-year-old male Mountain Lion (*Felis concolor*) died after chronic lameness in the Zoological Park "El Pinar", Caracas-Venezuela. Were practice euthanasia by prostration and anorexia. Grossly, there was xanthomatosis of subcutaneous tissue, the liver was swollen, friable and there was a nodular hyperplastic post necrotic lesion. The radio-ulnar-humeral joint had severe bilateral lesions on the surface of the articular cartilage, with erosion and exposure of subcondral bone (Fig. 1). There was approximately 1 ml of synovial fluid that was yellowish, and had a decreased viscosity. Histopathology revealed severe fatty degeneration, micronodular post necrotic hyperplasia with multifocal hepatic necrosis. The histological section of joint tissue revealed erosion and ulceration of articular cartilage, with variable degrees of exposure of the subcondral bone (Fig. 2). Bone tissue had defective osteoid matrix formation, and mineralization failure (Fig. 3), resulting in loss of bone lamellae. Radiographic changes included decreased cortical density, trabecular growth pattern, fractures and microfractures. Failure in the formation of bones callus, and presence of osteophytes.

These findings support the diagnosis of osteoarthritis and degenerative joint disease in a mountain lion kept in captivity. Nutritional problems are common in wild animals in captivity. There is abundant evidence that diet and health are intimately related. Feed intake is essential for normal metabolic function and deletions are inappropriate diet in disease. A disease is often a primary effect of a deficit or excess nutrients. The diet-deficit or excess of nutrients influence the course of diseases (3, 4). Hyperthyroidism in young adult cats is associated to secondary hyperparathyroidism due to increase of PTH and decrease of ionized calcium (7). Combined effects of thyroid hormones and PTH contribute to the reduction of bone mineral density (1).

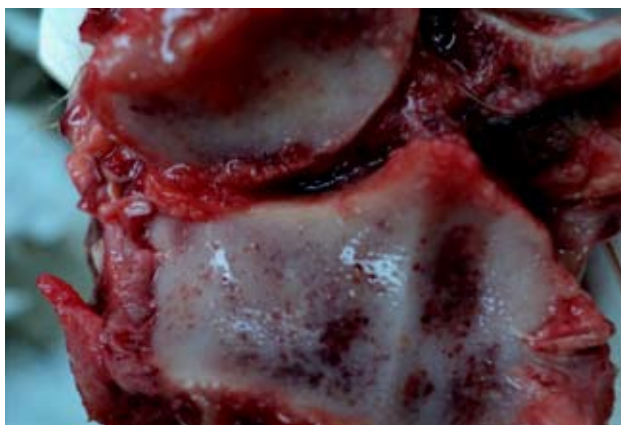


Figure 1.- Macroscopic aspect of the radio-ulnar-humerus joint of a mountain lion. There is severe damage in the articular cartilage with congestion, erosion and exposure extensive of subcondral bone bilateral.

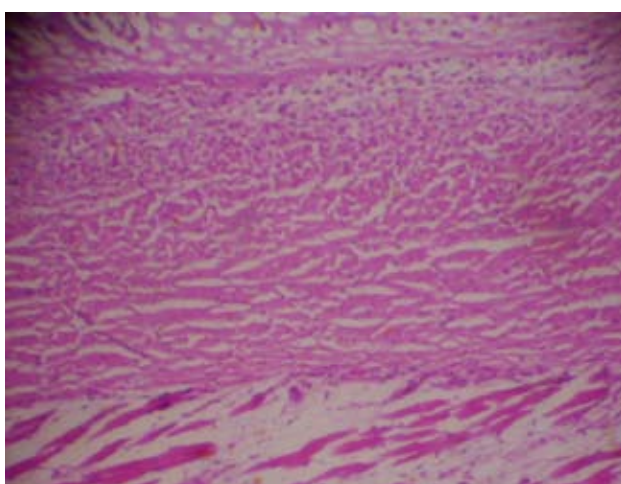


Figure 2.- The histological section of joint tissue revealed erosion and ulceration of articular cartilage, with varying degree of exposure of subcondral bone (H&E, obj. 10x).

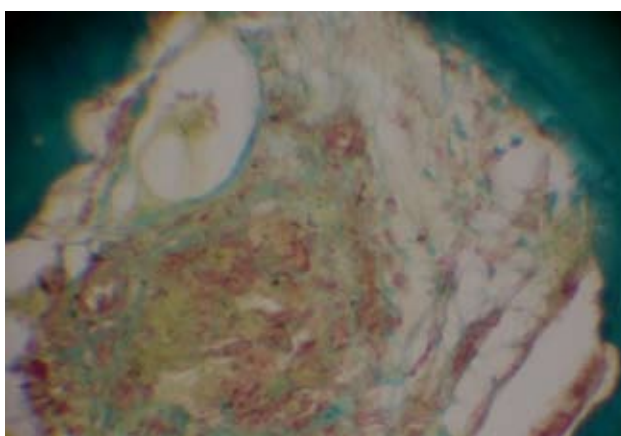


Figure 3.- The histological section of joint tissue revealed erosion and ulceration of articular cartilage, with varying degree of exposure of subcondral bone. (Von Kossa, obj. 10x).

In conclusion, were report describes a case of severe chronic osteoarthritis in a Mountain Lion (*Felis concolor*) kept in captivity. This is the first report on syndrome of osteoarthritis and degenerative joint disease in a mountain lion in a Zoological Park in Venezuela.

**REFERENCES**

1. Cardoso M, Costa F, Muniz L, Valerio M, Melussi M. Hyperparathyroidism in cats with experimental hyperthyroidism. *Arq Bras Med Vet Zootec.*, 2008. 60: 620-625.
2. Chesnev Rw, Hedberg G. Rickets in lion cubs at the London Zoo in 1889: some new insights. *Pediatrics.*, 2009. 123: 948.
3. Fowler, M. *Zoo & Wild Animal Medicine*. Second edition. W.B. Saunders Company. Philadelphia USA. 1986. pp. 71-96 pages.
4. Fowler M, Miller E. *Zoo & Wild Animal Medicine*. Current therapy 4. Philadelphia USA. 1999. pp. 63-82.
5. Hand M, Thatcher C, Remillard R, Roudebush P. *Small animal clinical nutrition*. Fourth edition. Mark Morris Institute. Santa Fe de Bogota Colombia. 2000. pp. 1097-1118.
6. Jubb K, Palmer N. *Pathology of Domestic Animals*. Second edition. Academic Press. New York. United State. 1985. pp. 126-138. Fifty edition available.
7. Herz V, Kirberger RM. Nutritional secondary hyperparathyroidism in a white lion cub (*Panthera leo*), with concomitant radiographic double cortical line. *J S Afr Vet Assoc.* Mar., 2004. 75: 49-53.